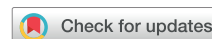

FOCUS TOPIC: PERI-OPERATIVE ECHOCARDIOGRAPHY

GUIDELINES AND STANDARDS

Guidelines for the Use of Transesophageal Echocardiography to Assist with Surgical Decision-Making in the Operating Room: A Surgery-Based Approach



From the American Society of Echocardiography in Collaboration with the Society of Cardiovascular Anesthesiologists and the Society of Thoracic Surgeons

Alina Nicoara, Chair, MD, FASE, Nikolaos Skubas, Co-Chair, MD, DSc, FASE, Niv Ad, MD, Alan Finley, MD, FASE, Rebecca T. Hahn, MD, FASE, Feroze Mahmood, MD, FASE, Sunil Mankad, MD, FASE, Charles B. Nyman, MBBCh, Francis Pagani, MD, PhD, Thomas R. Porter, MD, FASE, Kent Rehfeldt, MD, FASE, Marc Stone, MD, Bradley Taylor, MD, MPH, Annette Vegas, MD, FRCPC, FASE, Karen G. Zimmerman, BS, ACS, RDCS (AE, PE), RVT, FASE, William A. Zoghbi, MD, FASE, and Madhav Swaminathan, MD, FASE, *Durham, North Carolina; Cleveland, Ohio; Silver Spring and Baltimore, Maryland; Charleston, South Carolina; New York, New York; Boston, Massachusetts; Rochester, Minnesota; Ann Arbor and Traverse City, Michigan; Omaha, Nebraska; York, Pennsylvania; Toronto, Ontario, Canada; Houston, Texas*

Intraoperative transesophageal echocardiography is a standard diagnostic and monitoring tool employed in the management of patients undergoing an entire spectrum of cardiac surgical procedures, ranging from “routine” surgical coronary revascularization to complex valve repair, combined procedures, and organ transplantation. Utilizing a protocol as a starting point for imaging in all procedures and all patients enables standardization of image acquisition, reduction in variability in quality of imaging and reporting, and ultimately better patient care. Clear communication of the echocardiographic findings to the surgical team, as well as understanding the impact of new findings on the surgical plan, are paramount. Equally important is the need for complete understanding of the technical steps of the surgical procedures being performed and the complications that may occur, in order to direct the postprocedure evaluation toward aspects directly related to the surgical procedure and to provide pertinent echocardiographic information. The rationale for this document is to outline a systematic approach describing how to apply the existing guidelines to questions on cardiac structure and function specific to the intraoperative environment in open, minimally invasive, or hybrid cardiac surgery procedures. (J Am Soc Echocardiogr 2020;33:692-734.)

Keywords: Intraoperative, Transesophageal echocardiography, Cardiac surgery

From Duke University, Durham, North Carolina (A.N. and M.S.); Cleveland Clinic, Cleveland, Ohio (N.S.); White Oak Medical Center and University of Maryland, Silver Spring, Maryland (N.A.); Medical University of South Carolina, Charleston, South Carolina (A.F.); Columbia University, New York, New York (R.T.H.); Beth Israel Deaconess Medical Center, Harvard Medical School, Boston, Massachusetts (F.M.); Mayo Clinic, Rochester, Minnesota (S.M. and K.R.); Brigham and Women’s Hospital, Boston, Massachusetts (C.B.N.); University of Michigan, Ann Arbor, Michigan (F.P.); University of Nebraska Medical Center, Omaha, Nebraska (T.R.P.); Icahn School of Medicine at Mount Sinai, New York, New York (M.S.); University of Maryland Medical Center, Baltimore, Maryland (B.T.); Toronto General Hospital, Toronto, Ontario, Canada (A.V.); Munson Medical Center, Traverse City, Michigan (K.G.Z.); Houston Methodist Hospital, Houston, Texas (W.A.Z.).

The following authors reported no actual or potential conflicts of interest in relation to this document: Alina Nicoara, MD, FASE (Chair), Nikolaos Skubas, MD, FASE DSc (Co-Chair), Niv Ad, MD, Alan Finley, MD, FASE, Feroze Mahmood, MD, FASE, Sunil Mankad, MD, FASE, Francis Pagani, MD, PhD, Kent Rehfeldt, MD, FASE, Marc Stone, MD, Bradley Taylor, MD, MPH, Annette Vegas, MDCM, FRCPC, FASE, Karen G. Zimmerman, BS, ACS, RDCS (AE, PE), RVT, FASE, William A. Zoghbi, MD, FASE, Madhav Swaminathan, MD, FASE.

The following authors reported relationships with one or more commercial interests: Rebecca T. Hahn, MD, FASE reports speaker fees from Boston Scientific Corporation, Baylis Medical, Edwards Lifesciences and Medtronic; consulting for Abbott Structural, Edwards Lifesciences, Gore & Associates, Medtronic, Navi-

gate, and Philips Healthcare; non-financial support from 3mensio; equity with Navigate; and is the Chief Scientific Officer for the Echocardiography Core Laboratory at the Cardiovascular Research Foundation for multiple industry-sponsored trials, for which she receives no direct industry compensation. Charles B. Nyman, MBBCh, received educational honoraria from Edwards Lifesciences Ltd. and Baylis Medical, and owns common stock in Edwards Lifesciences Ltd. Thomas R. Porter, MD, FASE, received grant and equipment support from Philips Research North America and General Electric Global Research, and research support from Lantheus Medical Imaging and Astellas Pharma, Inc.

Attention ASE Members:

Visit www.ASELearningHub.org to earn free continuing medical education credit through an online activity related to this article. Certificates are available for immediate access upon successful completion of the activity. Nonmembers will need to join the ASE to access this great member benefit!

Reprint requests: American Society of Echocardiography, Meridian Corporate Center, 2530 Meridian Parkway, Suite 450, Durham, NC 27713 (E-mail: ase@asecho.org).

0894-7317/\$36.00

Copyright 2020 by the American Society of Echocardiography.

<https://doi.org/10.1016/j.echo.2020.03.002>

In addition to the collaborating societies listed in the title, this document is endorsed by the following American Society of Echocardiography International Alliance Partners: Argentine Society of Cardiology, Canadian Society of Echocardiography, Cardiovascular Imaging Society of the Interamerican Society of Cardiology (SISAC), Cardiovascular and Thoracic Society of Southern Africa, Chinese Society of Cardiothoracic and Vascular Anesthesiology, Chinese Society of Echocardiography, Department of Cardiovascular Imaging of the Brazilian Society of Cardiology, Indian Academy of Echocardiography, Indian Association of Cardiovascular Thoracic Anaesthesiologists, Iranian Society of Echocardiography, Israel Working Group on Echocardiography, Japanese Society of Echocardiography, Korean Society of Echocardiography, Mexican Society of Echocardiography and Cardiovascular Imaging (SOME-ic), National Association of Cardiologists of Mexico, Saudi Arabian Society of Echocardiography, Venezuelan Society of Cardiology - Echocardiography Section, Vietnamese Society of Echocardiography.

TABLE OF CONTENTS

1. Background and Rationale	693
2. General Principles	693
3. Valve Surgery	695
3.1. Mitral Valve	695
3.1.1. Preprocedure Assessment	695
3.1.2. Evaluation of Specific MV Pathologies	695
3.1.3. Assessment of Associated Lesions	698
3.1.4. TEE in Minimally Invasive and Robotic Mitral Valve Surgery	700
3.1.5. Postprocedure Assessment	701
3.2. Aortic Valve	702
3.2.1. Preprocedure Assessment	702
3.2.2. Evaluation of Specific AV Pathologies	704
3.2.3. Assessment of Associated Lesions	705
3.2.4. Postprocedure Assessment	706
3.3. Tricuspid Valve	711
3.3.1. Preprocedure Assessment	711
3.3.2. Evaluation of Specific TV Pathologies	711
3.3.3. Postprocedure Assessment	712
3.4. Pulmonary Valve	712
3.4.1. Preprocedure Assessment	712
3.4.2. Evaluation of Specific PV Pathologies	712
3.4.3. Postprocedure Assessment	713
4. Coronary Artery Disease	714
4.1. Preprocedure Assessment	714
4.2. Postprocedure Assessment	716
5. Aortic Surgery	716
5.1. Preprocedure Assessment	716
5.2. Evaluation of Specific Aortic Pathologies	716
5.3. Postprocedure Assessment	717
6. Mechanical Circulatory Support	719
6.1. Left Ventricular Assist Device	719
6.1.1. Preprocedure Assessment	719
6.1.2. Postprocedure Assessment	724
6.2. Percutaneous Devices	724
6.3. Right Ventricular Assist Devices	725
6.4. Total Artificial Heart	725
6.5. Extracorporeal Membrane Oxygenation	726
6.6. Intra-aortic Balloon Pump	726
7. Hypertrophic Cardiomyopathy	726
7.1. Preprocedure Assessment	726
7.2. Postprocedure Assessment	727
8. Heart Transplantation	727
9. Lung Transplantation	728
10. Pericardial Diseases	729
11. Tumors and Intracardiac Masses	729
12. Summary	729

1. BACKGROUND AND RATIONALE

Intraoperative transesophageal echocardiography (TEE) is a standard diagnostic and monitoring tool employed in the management of pa-

tients undergoing an entire spectrum of cardiac surgical procedures, ranging from surgical coronary revascularization to complex valve repair, combined procedures, and organ transplantation.¹

The operating room is a dynamic environment with unique challenges. Combinations of echocardiographic modalities, including two-dimensional (2D), three-dimensional (3D), color flow and/or spectral Doppler, and cardiac mechanics, are used to (1) confirm the preoperative diagnosis, (2) evaluate interval changes, (3) guide surgical interventions and hemodynamic management, (4) assess results of the surgical procedure, and (5) diagnose the etiology of hemodynamic disturbances. Hemodynamic fluctuations, electrical pacing, positive pressure ventilation, fluid shifts, and surgical maneuvers can impact echocardiographic evaluation. Frequently, despite interruptions and stressors, decisions may have to be made urgently depending on patient and surgical factors. While a complete echocardiographic evaluation is always recommended and desirable, it may not always be possible due to the urgency of the procedure, competing clinical tasks, or surgical maneuvers.

Existing guidelines by the American Society of Echocardiography (ASE) comprehensively describe the application of ultrasound examinations in the evaluation of cardiac structures (e.g., valvular regurgitation or stenosis of native or prosthetic heart valves),^{2,3} or congenital heart disease,⁴ as well as the principles, purpose and implementation of specialized techniques (e.g., three-dimensional imaging, cardiac deformation).^{5,6}

The rationale for this document is not to re-write existing comprehensive ASE practice guidelines or recommendations but rather to outline a systematic approach on how to apply the existing guidelines to questions on cardiac structure and function specific to the intraoperative environment in open, minimally invasive, or hybrid procedures. This document will not address application of intraprocedural echocardiography in structural heart disease (e.g., transcatheter valve procedures). The recommendations of this writing group are based on expert consensus and available evidence at the time of writing, including existing and pertinent guidelines from the ASE, Society of Cardiovascular Anesthesiologists (SCA), American Heart Association (AHA), American College of Cardiology (ACC), American Society of Anesthesiologists (ASA), and related organizations.

2. GENERAL PRINCIPLES

Practice guidelines for the use of perioperative TEE were developed by the ASA and the SCA in 1996⁷ and further refined in 2010.¹ Based on these documents, TEE should be used in adults without contraindications for all open heart and thoracic aortic surgical procedures, and should be considered in coronary artery bypass grafting surgeries to: (1) confirm and refine the preoperative diagnosis, (2) detect new or unsuspected pathology, (3) adjust the anesthetic and surgical plan, and (4) assess the results of the surgical intervention.¹

Abbreviations

2Ch = Two-chamber
2D = Two-dimensional
3D = Three-dimensional
4Ch = Four-chamber
5Ch = Five-chamber
ACC = American College of Cardiology
AHA = American Heart Association
AS = Aortic stenosis
ASA = American Society of Anesthesiologists
ASD = Atrial septal defect
ASE = American Society of Echocardiography
AR = Aortic regurgitation
AV = Aortic valve
AVA = Aortic valve area
AVR = Aortic valve replacement
BSA = Body surface area
CABG = Coronary artery bypass graft
CAD = Coronary artery disease
CFD = Color flow Doppler
CPB = Cardiopulmonary bypass
CW = Continuous-wave
CS = Coronary sinus
DVI = Doppler velocity index
ECG = Electrocardiogram
ECMO = Extracorporeal membrane oxygenation
EROA = Effective regurgitant orifice area
FAC = Fractional area change
HCM = Hypertrophic cardiomyopathy
IABP = Intra-aortic balloon pump
IAS = Interatrial septum
IVC = Inferior vena cava
IVS = Interventricular septum
LA = Left atrium/left atrial
LAA = Left atrial appendage
LAX = Long-axis
LSCA = Left subclavian artery
LV = Left ventricle/ventricular
LVAD = Left ventricular assist device
LVH = Left ventricular hypertrophy

LVOT = Left ventricular outflow tract
MC = Mitral commissural
MCS = Mechanical circulatory support
ME = Mid-esophageal
MS = Mitral stenosis
MV = Mitral valve
MVA = Mitral valve area
OHT = Orthotopic heart transplantation
PA = Pulmonary artery
PFO = Patent foramen ovale
PHT = Pressure half-time
PHV = Prosthetic heart valves
PISA = Proximal isovelocity surface area
PLSVC = Persistent left superior vena cava
PR = Pulmonic regurgitation
PS = Pulmonic stenosis
PV = Pulmonary veins/venous
PW = Pulsed-wave
RA = Right atrium/atrial
RHF = Right heart failure
RV = Right ventricle/ventricular
RVAD = Right ventricular assist device
RVOT = Right ventricular outflow tract
SAM = Systolic anterior motion
SAX = Short-axis
SCA = Society of Cardiovascular Anesthesiologists
SVC = Superior vena cava
TA = Tricuspid annulus/annular
TAH = Total artificial heart
TAPSE = Tricuspid annular plane systolic excursion
TEE = Transesophageal echocardiography
TG = Transgastric
TR = Tricuspid regurgitation
TS = Tricuspid stenosis
TTE = Transthoracic echocardiography
UE = Upper esophageal
VA = Veno-arterial
VAD = Ventricular assist devices
VSD = Ventricular septal defect
VV = Veno-venous

A discussion with the surgery team prior to surgical incision will help the echocardiographer set the goals of the exam, keeping the surgical plan in perspective. For most elective surgeries, the severity of the pathology being treated has often been established already by preoperative imaging. Therefore, the goal of the exam is to confirm known findings and exclude additional pathology that may alter the surgical plan. Examples include the incidental finding of a persistent left superior vena cava (PLSVC), which could alter the manner in which retrograde cardioplegia is delivered; or a patent foramen ovale (PFO), which could require a change in venous cannulation strategy if a PFO repair is necessary. A comprehensive exam may also discover severe aortic atherosclerotic disease, which, depending on location, could alter the location of the aortic cannulation or cross-clamp, or the decision to insert an intra-aortic balloon pump.

In emergent cases (e.g., aortic dissection, tamponade), the goal of the intraoperative exam is to confirm the suspected diagnosis for surgery, establish the extent of associated complications, and define the etiology of hemodynamic instability (abnormal wall motion, effusion, dissection). Patients presenting for urgent and emergent surgery for infective endocarditis should undergo careful assessment not only of valvular lesions but especially of perivalvular complications which may have developed due to rapid progression of the disease. Findings such as aortic root abscess and/or pseudoaneurysm, intervalvular fibrosa abscess, intracardiac fistulas, or prosthetic dehiscence could dramatically alter the surgical plan.

A critical component of the intraoperative exam is clear communication of the echocardiographic findings to the surgical team. Changes in surgical plan have to be carefully considered within the clinical context as part of a team discussion. As intraoperative echocardiographic findings aid in postoperative management, a report (written or electronic) generated at the end of the procedure and summarizing the key elements of the intraoperative examination facilitates communication with the postoperative care team.

During open-chamber surgery for left-sided lesions, prior to discontinuation of cardiopulmonary bypass (CPB), echocardiography is particularly valuable during assistance with de-airing. Following the completion of surgery, an early echocardiographic exam should focus on assessment of the surgery (repair, replacement), and any unintended consequences (e.g., wall motion abnormalities, iatrogenic aortic dissection, immobile prosthetic valve leaflets). The early principal goal is the assessment of any findings that indicate a structural problem, which may require immediate surgical intervention.

A focused approach is therefore valuable but should not preclude the performance of a comprehensive examination to ensure no additional new findings. The presence of inotropic support, electrical pacing, and volume shifts should also be considered when interpreting echocardiographic measurements.

3. VALVE SURGERY

3.1. Mitral Valve

The mitral valve (MV) is one of the most anatomically and functionally complex structures in the heart. Although transthoracic echocardiography (TTE) is the imaging standard for preoperative diagnosis and postoperative follow-up, TEE is the preferred imaging modality in the intraoperative and immediate postoperative period.

3.1.1. Preprocedure Assessment. While grading of the severity of MV functional abnormality is best performed by TTE under

“awake” physiologic conditions,² TEE is best suited for a detailed description of MV anatomical features, including mechanism of disease and location and extent of valvular lesions, which are prerequisites of surgical decision-making.

Comprehensive TEE examination of the mitral valve is described in prior ASE guidelines documents.^{2,8} Briefly, the mitral valve apparatus is assessed using mid-esophageal (ME) 4-chamber (4Ch), mitral commissural (MC), two-chamber (2Ch), and long-axis (LAX) views, as well as transgastric (TG) basal short-axis (SAX), mid-papillary SAX, 2Ch, and LAX views, and the deep TG 5-chamber (5Ch) view. Simultaneous multiplane imaging of ME or TG views may be used. By positioning (tilting) the cursor on a particular area in the primary/reference view, further detailed anatomic imaging is provided in the secondary/orthogonal view. Addition of color flow Doppler (CFD) will identify areas of abnormal flow acceleration on either side of valve leaflets. However, lower temporal resolution seen with CFD should be taken into consideration when imaging mobile lesions, such as endocarditis vegetations or chordae tendineae.

While scanning from ME windows, any 3D-echocardiographic acquisition mode (wide angle, narrow angle, user-defined, and CFD) can be used. A wide-angle 3D data set (generated either from a full volume or zoom mode) may require electrocardiogram (ECG)-gated, multi-beat acquisition to improve both spatial and temporal resolution; however this may be challenging in the operating room due to the electrical interference from electrocautery. Excessive translation of the heart during mechanical ventilation may result in the creation of stitch artifacts, and breath holds may be required. Real-time, narrow-angle, single-beat 3D imaging may be a more rapid way to interrogate the MV apparatus, however the narrow sector may eliminate landmarks necessary for locating and orienting specific structures. These same principles can be used to acquire 3D CFD volumes although low temporal resolution in all 3D acquisition modes will typically require multi-beat spliced images.

By using 3D acquisition, the MV can be examined as per ASE guidelines from either the left atrial (LA) or left ventricular (LV) perspective (Figure 1).⁶ The MV should be oriented with the aortic valve (AV) at the top of the screen in the 12 o'clock position regardless if viewed from the left atrial or the left ventricular perspective. Including the AV, interatrial septum (IAS), or the left atrial appendage (LAA) in the acquired 3D data set facilitates anatomic orientation with the IAS adjacent to the medial, and the LAA adjacent to the lateral, MV commissure. Utilizing simultaneous multiplane imaging may allow better appreciation of the relative anatomy and spatial relationship between the annulus and leaflets, with adjacent structures.

An intraoperative comprehensive TEE examination of the MV should include imaging and evaluation of the LA and LV. Although the size of the LA cannot be accurately quantified by TEE,⁹ its antero-posterior diameter at mid-systole in the ME AV SAX view should be measured as it correlates best with TTE-derived volumetric data.^{10,11}

3.1.2. Evaluation of Specific MV Pathologies. Mitral Stenosis.

–The etiology and mechanism of mitral stenosis (MS) (rheumatic versus degenerative) should be evaluated and confirmed by 2D and 3D echocardiographic assessment. Specifically, the severity and distribution of calcification in the mitral annulus and extension into the leaflets may impact surgical planning.

Quantification of MS should be based on the current European Association of Echocardiography/ASE guidelines using a multi-parametric approach,¹² with the important caveat that many standard measures of MS severity for rheumatic disease have not been validated for degenerative MS.

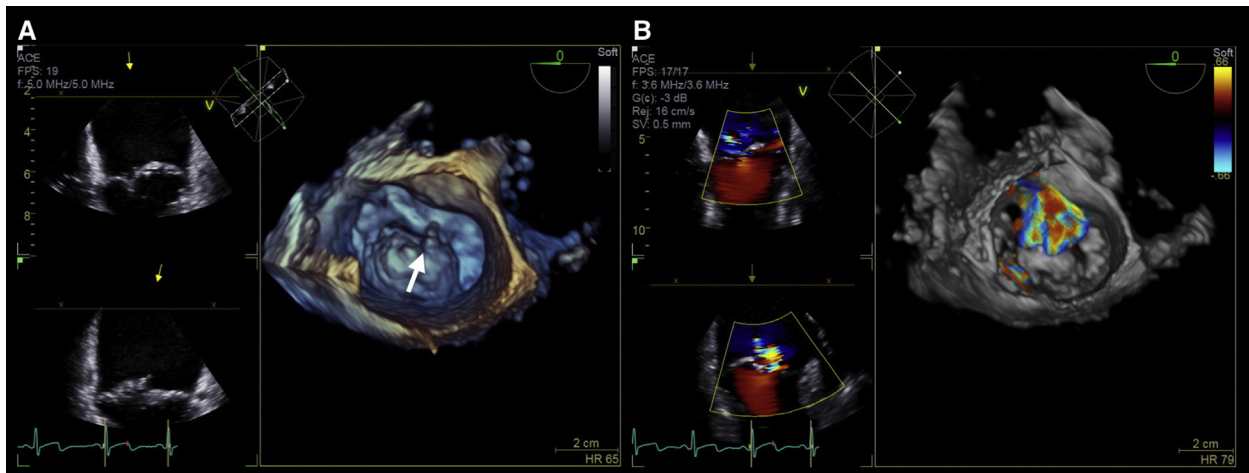


Figure 1 (A) Mitral valve seen en face in a 3D data set from the left atrial perspective (“surgeon’s view”). Flail large P2 segment can be seen (white arrow). (B) Mitral regurgitation jet seen with color flow Doppler, originating at the level of the flail P2 segment and directed anteriorly.

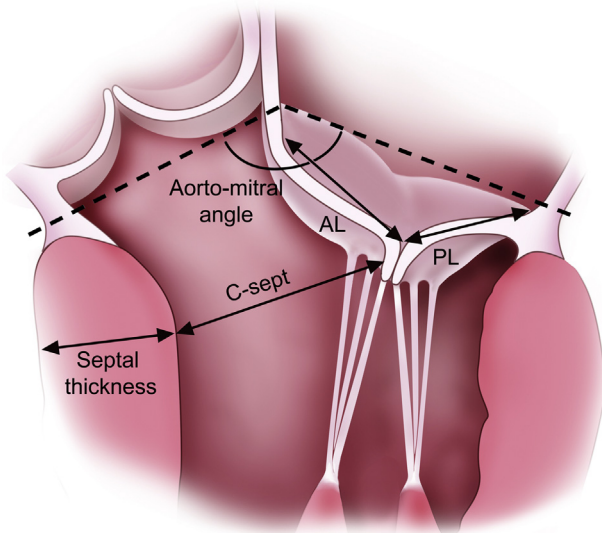


Figure 2 Echocardiographic measurements for predicting the risk of systolic anterior motion after mitral valve repair. Abbreviations: AL, Anterior leaflet height measured from the aortic annulus to the coaptation point; C-sept, distance from the coaptation point to the interventricular septum measured at end-systole perpendicular to the septum; PL, posterior leaflet height measured from the aortic annulus to the coaptation point.

The anatomic mitral valve area (MVA) is traced in mid-diastole using 2D TEE (TG basal SAX with simultaneous orthogonal imaging of TG 2Ch view) to locate the narrowest orifice of the “funnel”-shaped MV, or with 3D echo-based multiplanar reconstruction and direct planimetry of the narrowest orifice. Gain settings should be optimized, particularly in 3D data sets, as excessive gain can underestimate the MVA especially when leaflet tips are densely calcified, resulting in acoustic noise and artificial thickening of the valve structures.¹²

Parameters of Doppler interrogation, such as pressure half-time and pressure gradients, should be used to confirm the severity of rheumatic MS prior to surgery. It is important to remember that these measurements are influenced by hemodynamic factors such as

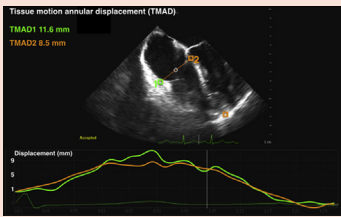
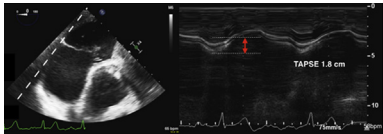
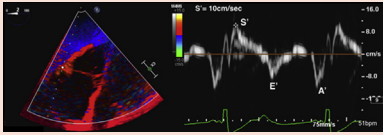
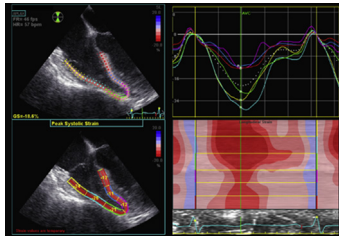
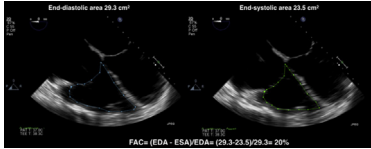
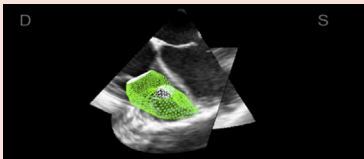
transvalvular flow and heart rate, which may be dynamic under general anesthesia, as well as by the presence of coexistent valvular lesions (e.g., mitral regurgitation [MR], aortic regurgitation [AR]) and diastolic dysfunction. Low flow, low gradient MS has been well-described and a multi-parametric approach (often utilizing planimetry) is essential.¹²

Mitral Regurgitation.—The intraoperative determination of the severity of MR is important in specific clinical situations, including (1) when interval changes have occurred in cases of unplanned MV surgery, such as in elective coronary artery bypass graft (CABG), or AV surgery; (2) unclear etiology or severity of MR; or (3) incomplete pre-operative work-up when surgery is urgent or emergent, or due to poor transthoracic acoustic windows.

A detailed interrogation of the entire mitral annulus and MV leaflets with 2D and 3D imaging will help identify the mechanism of MR, and the location and extent of valvular lesions as recommended in the ASE/Society for Cardiovascular Magnetic Resonance native valve regurgitation assessment guidelines.² Important findings to report include identification of clefts (visible in diastole), scallops/segments and accompanying sub-valvular structures with excessive motion, and leaflet appearance (thickness, masses/vegetations, calcification) and motion.

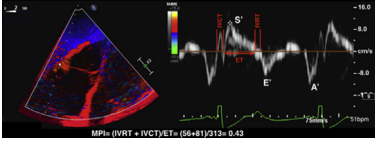
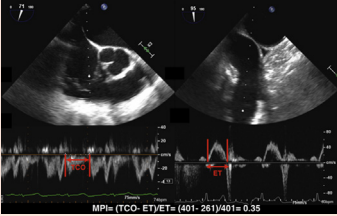
The risk for systolic anterior motion (SAM) after MV repair should be assessed prior to surgical intervention. A myxomatous MV with redundant leaflets, especially excessive anterior leaflet tissue, and a non-dilated hyperdynamic left ventricle, are frequent predisposing factors.² In the ME 5Ch or ME LAX views, the lengths of the posterior and anterior MV leaflets (in mid-diastole), the ratio of the anterior and posterior leaflet heights measured at end-systole from the mitral annulus to the coaptation point, the end-systolic distance from the coaptation point perpendicular to the interventricular septum (IVS), also known as the “C-sept distance”, and the angle between the MV and AV planes should be measured (Figure 2). These measurements can also be performed by multiplanar reconstruction of 3D data sets, which enables manipulation of the position of the plane of measurement and elimination of the parallax error due to oblique orientation.¹³ Independent predictors of SAM post MV repair include: a thick basal interventricular septum (>15 mm), a short C-sept distance (<25 mm), a narrow aorto-mitral angle (<120°),

Table 1 Echocardiographic assessment of right ventricular function using transesophageal echocardiographic methods

Echocardiographic parameter	Imaging modality	Limitations
Longitudinal function		
Tricuspid annular plane systolic excursion (TAPSE)		
<p>Speckle tracking</p> 	<p>Speckle tracking ME 4-chamber RV focused Post-processing software based on speckle-tracking technology is used to track motion and displacement of the lateral tricuspid annulus toward the RV apex.</p>	<ul style="list-style-type: none"> • Neglects wall motion abnormalities • Neglects contribution of RVOT • Influenced by overall movement of the heart • May be decreased in patients with otherwise normal RV function who have undergone cardiac surgery with cardiopulmonary bypass and pericardiectomy • Vendor dependent (speckle tracking)
<p>M-mode</p> 	<p>M-mode Modified deep TG 5-chamber Alignment of the M-mode cursor with the longitudinal motion of the lateral tricuspid annulus should be achieved. TAPSE measured from end-diastole to end-systole Abnormal TAPSE <1.7cm</p>	<ul style="list-style-type: none"> • Angle dependency (M-mode)
<p>Pulsed-wave tissue Doppler imaging (S')</p> 	<p>Peak systolic velocity of the tricuspid annulus by pulsed-wave TDI ME RV inflow-outflow Modified deep TG 5-chamber TG RV inflow-outflow Ensure best alignment of the Doppler beam with the motion of the lateral tricuspid annulus. May require angle correction Abnormal RV S' <9.5 cm/sec</p>	<ul style="list-style-type: none"> • Angle dependency • Neglects wall motion abnormalities • Neglects the contribution of the RVOT
<p>Global longitudinal strain</p> 	<p>Speckle tracking ME 4-chamber Peak value of longitudinal strain measured using specialized software, averaged over the three segments of the RV free wall Abnormal RV GLS < 20% (in magnitude)</p>	<ul style="list-style-type: none"> • Vendor dependent • Absence of RV-specific software
Global function		
<p>Fractional area change (FAC)</p> 	<p>2D measurement ME 4-chamber RV focused $FAC (\%) = (EDA - ESA) / EDA \times 100$ Abnormal FAC <35%</p>	<ul style="list-style-type: none"> • Requires good delineation of the endocardium • Prominent trabeculations may introduce errors • Neglects contribution of RVOT
<p>Ejection fraction (EF)</p> 	<p>3D measurement $RVEF (\%) = (EDV - ESV) / EDV \times 100$ Abnormal RVEF <45%</p>	<ul style="list-style-type: none"> • Requires good quality data sets • Requires specialized software and operator expertise

(Continued)

Table 1 (Continued)

Echocardiographic parameter	Imaging modality	Limitations
<p>Tissue Doppler imaging MPI</p> 	<p>ME RV inflow-outflow Modified deep TG 5-chamber TG RV inflow-outflow MPI = (IVRT + IVCT)/ ET Abnormal TDI MPI >0.54</p>	<ul style="list-style-type: none"> • Unreliable when RA pressures are elevated • Regional measurement • Requires good quality spectral tissue Doppler for time interval measurements
<p>Pulsed-wave Doppler MPI</p> 	<p>ME RV inflow-outflow TG RV basal UE aortic arch SAX MPI = (TCO - ET)/ET Abnormal PW MPI >0.43</p>	<ul style="list-style-type: none"> • Unreliable when RA pressures are elevated • Measurements are performed in different cardiac cycles

Abbreviations: *EDA*, End-diastolic area; *EDV*, end-diastolic volume; *ESA*, end-systolic area; *ESV*, end-systolic volume; *ET*, ejection time; *IVCT*, isovolumic contraction time; *IVRT*, isovolumic relaxation time; *RA*, right atrium; *RV*, right ventricle; *RVOT*, right ventricular outflow tract; *TCO*, tricuspid valve closure to opening time.

Adapted for transesophageal echocardiographic assessment from Lang RM, Badano LP, Mor-Avi V, Afilalo J, Armstrong A, Ernande L, et al, *J Am Soc Echocardiogr* 2015; 28:1-39

anterior displacement of the papillary muscles, and a ratio between the lengths of the anterior and posterior leaflets ≤ 1.3 .^{14,15}

LV dysfunction and dilation may lead to apical displacement of the papillary muscles and the shift of the coaptation point below the mitral annular plane, resulting in a tented appearance of the valve in systole. The degree of tenting can be used as a surrogate marker for the chronicity and significance of MR. The distance between the plane of the mitral annulus and the coaptation point at mid-systole (tenting height) is measured in the ME 5Ch or ME LAX view. The tethering angles of the anterior or posterior leaflet may be measured in mid-systole as the angle between the mitral annular plane and the coaptation point along the leaflet. Tenting indices, such as MV tenting height, area, and volume, can be measured with post-processing multiplanar reconstruction or parametric analysis of 3D data sets.

Qualitative assessment of MR severity is based upon the CFD characteristics of the MR jet; however, this may be influenced by technical factors, loading conditions, and jet eccentricity. It is important to describe the number, origin, and direction of MR jets. The direction of the MR jet is typically away from an area with excessive motion (e.g., in primary/structural/organic MR) or toward an area with restricted motion (e.g., in secondary MR). An eccentric, "wall hugging" MR jet is suggestive of moderate or severe MR.

The vena contracta width measurement may underestimate the severity of MR, if the MR jet has a non-circular, elliptical cross-sectional area.¹⁶ The same limitation exists for calculating the effective MR orifice area using the proximal isovelocity surface area (PISA) method; the actual surface is rarely a hemisphere but rather a hemi-ellipse. If multiple jets are present, neither the vena contracta widths nor the effective orifice areas by the PISA method should be summed. Measurements of the vena contracta width and area can be performed by multiplanar reconstruction using a 3D data set, although these measurements are impacted by the low temporal and spatial resolution of the 3D data set. However, recent enhancements in 3D technology have improved the temporal resolution of the 3D data sets.

LV size and function are evaluated in the same ME and TG views used for anatomic evaluation of the MV. Larger LV and LA sizes are suggestive of chronic MR. Evaluation of LV size and function (global and regional) by TEE may be hindered by the presence of mitral annular calcification, which obscures the respective LV segments in the far field due to acoustic shadowing. The morphology of the basal IVS should be evaluated for the presence of focal hypertrophy. CFD can be used to localize any intraventricular, mid-cavitary, or left ventricular outflow tract (LVOT) flow acceleration.

The proximity of the TEE probe to the LA and pulmonary veins (PV) makes evaluation of the PV flow with pulsed-wave (PW) Doppler an attractive complementary, qualitative technique to estimate MR severity. Systolic reversal in more than one PV is a specific, yet insensitive, indicator of severe MR.²

The severity of MR varies with the changing intraoperative hemodynamic conditions. While structural MV pathology is not significantly affected by general anesthesia, the severity of functional MR may improve under general anesthesia compared with the preoperative findings.¹⁷ In general, changes in preload, afterload and contractility are usually responsible for inaccurate measurements (typically underestimation) of functional MR under general anesthesia. In cases of functional MR, more so when MR is an incidental finding, intravenous fluids and inotropic and afterload challenges should be attempted to avoid erroneous estimation of MR severity.¹⁷

3.1.3. Assessment of Associated Lesions. Functional tricuspid regurgitation (TR) is frequently present in patients with MV disease. A comprehensive evaluation of the TV, including the tricuspid annulus, should be performed at the time of surgery (section 3.3).

There is also increased recognition that right ventricular (RV) dysfunction is common in patients undergoing MV surgery. While RV function may improve postoperatively in most patients, it may remain reduced or deteriorate in others.¹⁸ The position of the interventricular septum (IVS) and RV size and function, typically in the ME 4Ch and TG SAX views, provide information on RV dysfunction

Table 2 Key points for the pre-surgical assessment in mitral valve surgery

Imaging goals	Imaging views	Imaging modalities	Limitations
Evaluate MV anatomy	ME: 4Ch, MC, 2Ch, LAX TG: basal SAX, 2Ch, LAX	<ul style="list-style-type: none"> • 2D, bi/multiplane • CFD • 3D +/- CFD 	<ul style="list-style-type: none"> • 2D: off-axis orientation and measurements • 3D: low temporal resolution, stitch artifacts in gated acquisition
Evaluate MS severity Mean pressure gradient; MVA by PHT, PISA; MVA by continuity equation; MVA by planimetry (2D, 3D)	ME: 4Ch, MC, 2Ch, LAX TG: basal SAX, 2Ch, deep 5Ch	<ul style="list-style-type: none"> • 2D, bi/multiplane imaging • 3D, multiplanar reconstruction • CFD: PISA • Spectral Doppler: mean pressure gradient, PHT, LVOT SV 	<ul style="list-style-type: none"> • 2D: off-axis measurements, acoustic shadowing • Doppler beam misalignment; HR/rhythm dependent; • Coexistent valvular lesions
Evaluate MR severity (acute vs chronic MR) Jet origin, direction; Vena contracta width; EROA by PISA; TMF and PVF; Regurgitant volume/fraction	ME: 4Ch, MC, 2Ch, LAX	<ul style="list-style-type: none"> • M-mode with CFD: timing of MR during systole • CFD: MR jet characteristics and quantification (EROA by PISA, vena contracta width/jet area) • 3D with CFD: vena contracta width and area • Spectral Doppler: MR jet envelope (Vmax, VTI); TMF and PVF profiles 	<ul style="list-style-type: none"> • Eccentric or wall-hugging MR jet (Coanda effect) • 3D with CFD: low temporal and spatial resolution • PVF: preload dependent • TMF: influenced by LV diastolic function and AR; preload dependent • Doppler beam misalignment
Evaluate “failure-prone” anatomy Primary MR: SAM Secondary MR: tethering and tenting	ME: 4Ch, MC, 2Ch, LAX AL and PL length, C-sept distance, AL:PL height ratio, Mitral-aortic angle, Basal IVS thickness Tenting height/area	<ul style="list-style-type: none"> • 2D, bi/multiplane imaging • 3D multiplanar reconstruction • Doppler interrogation 	<ul style="list-style-type: none"> • 2D: off-axis measurements
Evaluate LV systolic function Global/regional Evaluate LV size LV dimensions and volume	ME: 4Ch, MC, 2Ch, LAX TG: basal and mid SAX, 2Ch, deep 5Ch, LAX	<ul style="list-style-type: none"> • 2D: method of disks • 3D: volumetric • Spectral Doppler: LVOT SV • M-mode: internal linear dimensions 	<ul style="list-style-type: none"> • 2D: LV foreshortening • 3D: low spatial and temporal resolution • Erroneous LVOT diameter measurement • Off-axis measurements
Evaluate LA and LAA LA size; Stasis, thrombus, LAA velocities	ME: 4Ch, MC, 2Ch	<ul style="list-style-type: none"> • 2D, bi/multiplane imaging • CFD • Spectral Doppler: PVF profile • 3D 	<ul style="list-style-type: none"> • Close proximity of LA with TEE probe • Presence of artifacts in LAA
Evaluate RA size Evaluate RV size/function	ME: 4Ch, RV in/outflow, bicaval	<ul style="list-style-type: none"> • 2D • CFD • Spectral Doppler • M-mode 	<ul style="list-style-type: none"> • Misalignment for TAPSE evaluation • Complex RV geometry

(Continued)

Table 2 (Continued)

Imaging goals	Imaging views	Imaging modalities	Limitations
Evaluate TR	ME: 4Ch, RV inflow/ outflow, bicaval	<ul style="list-style-type: none"> • 2D • CFD 	<ul style="list-style-type: none"> • Doppler misalignment • Alteration in hemodynamic conditions
Measure TA	ME 4Ch	<ul style="list-style-type: none"> • 2D • 3D multiplanar reconstruction 	<ul style="list-style-type: none"> • 2D: off-axis measurements • 3D: low spatial resolution

Abbreviations: *2Ch*, Two-chamber; *4Ch*, four-chamber; *5Ch*, five-chamber; *2D*, two-dimensional; *3D*, three-dimensional; *AL*, anterior leaflet; *AR*, aortic regurgitation; *CFD*, color flow Doppler; *C-sept*, distance from septum to mitral valve coaptation point; *EROA*, effective regurgitant orifice area; *IVS*, interventricular septum; *LAA*, left atrial appendage; *LAX*, long axis; *LV*, left ventricle; *LVOT*, left ventricular outflow tract; *ME*, mid-esophageal; *MC*, mitral commissural; *MR*, mitral regurgitation; *MS*, mitral stenosis; *MV*, mitral valve; *MVA*, mitral valve area; *PISA*, proximal iso-velocity surface area; *PHT*, pressure half-time; *PVF*, pulmonary vein flow; *PL*, posterior leaflet; *RA*, right atrium; *RV*, right ventricle; *SAM*, systolic anterior motion; *SAX*, short axis; *SV*, stroke volume; *TAPSE*, tricuspid annulus systolic excursion; *TA*, tricuspid annulus; *TG*, transgastric; *TMF*, transmitral flow; *TR*, tricuspid regurgitation; *V_{max}*, peak velocity; *VTI*, velocity-time integral.

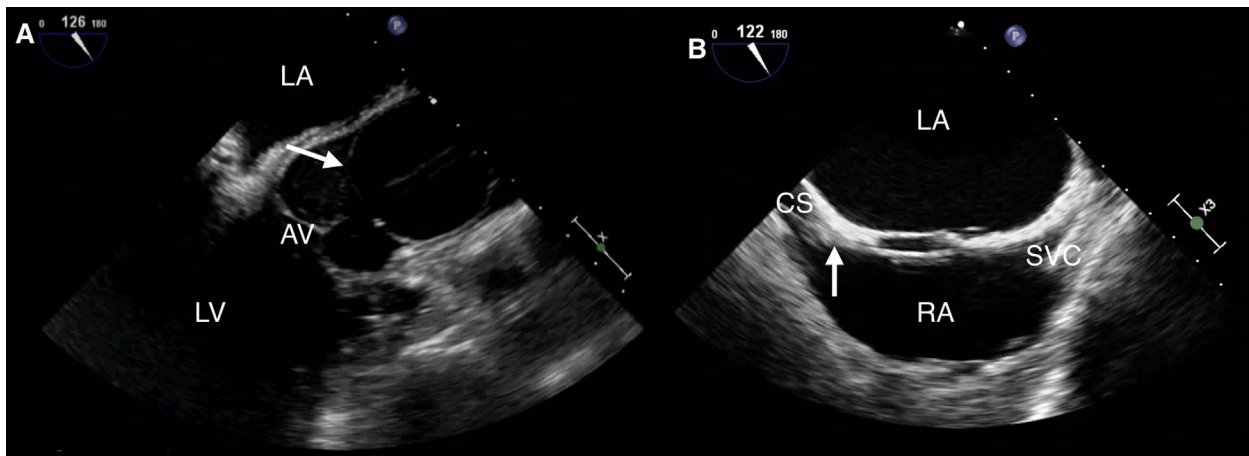


Figure 3 (A) ME aortic valve LAX view showing an inflated endoballoon positioned above the sinotubular junction and occluding the ascending aorta. (B) ME bicaval view showing a coronary sinus catheter for retrograde cardioplegia administration (white arrow) entering the right atrium (RA) through the superior vena cava (SVC) and engaging the coronary sinus (CS). Abbreviations: AV, Aortic valve; LA, left atrium; LV, left atrium.

and/or volume or pressure overload in the setting of left-heart disease. A summary of methods and parameters used for assessment of RV function by TEE is presented in [Table 1](#)

The LA and its appendage should be interrogated for low flow (stasis/spontaneous contrast) and presence of thrombus. In MS, the presence of an LA or LAA thrombus may alter the surgical plan, resulting in ligation or surgical closure of the appendage. The intraoperative assessment of the LAA should be performed by 2D (multiplane angle 0° to 180°), Doppler, and 3D echocardiography as described by existing guidelines.⁸

Key points regarding preprocedure assessment for MV surgery are presented in [Table 2](#).

3.1.4. TEE in Minimally Invasive and Robotic Mitral Valve Surgery. Both port-access minimally invasive and robotic MV surgery use a catheter-based system that enables closed-chest CPB and allows the heart to be arrested and protected with cardioplegic solu-

tion in a fashion similar to conventional open-chest surgery. With procedures that do not involve cannulation through the chest, all catheters used for CPB and cardioplegia delivery are placed percutaneously; intraoperative TEE guides placement of the catheters and monitors their function during CPB.¹⁹

A *venous outflow cannula* used for venous drainage is inserted via the femoral vein and inferior vena cava (IVC) into the right atrium (RA), at the junction of the superior vena cava (SVC) with the RA. The ME bicaval view is used to visualize the guidewire entering the RA from the IVC and engaging the SVC. Similarly, the venous cannula should be visualized as it enters the RA and engages the SVC.

A *femoral arterial cannula* providing arterial inflow from the CPB is a balloon-tipped catheter that is used for endovascular occlusion of the ascending aorta, delivery of cardioplegia into the aortic root, venting of the aortic root, and aortic root pressure measurement. Visualization of the guidewire entering the descending aorta from the femoral artery and extending into the ascending aorta ensures positioning of the tip of the balloon-tipped catheter in the ascending aorta (above

Table 3 Key points for the post-surgical assessment for mitral valve surgery

Imaging goals	Imaging views	Imaging modalities	Limitations
Evaluate residual or new MR	ME: 4Ch, MC, 2Ch, LAX	<ul style="list-style-type: none"> • 2D, bi/multiplane imaging • CFD • 3D +/- CFD 	<ul style="list-style-type: none"> • Dependent on preload, afterload, contractility, and heart rate after separation from CPB
Evaluate MV leaflet motion Exclude iatrogenic MS Mean pressure gradient; MVA planimetry (3D); MVA continuity equation	ME: 4Ch, MC, 2Ch, LAX TG: deep 5Ch, LAX	<ul style="list-style-type: none"> • 2D, bi/multiplane imaging • 3D, multiplanar reconstruction • Spectral Doppler (PW: LVOT SV, CW: transmitral flow) 	<ul style="list-style-type: none"> • Funnel-shaped MVA • Acoustic shadowing • Co-existent valvular lesions
Evaluate SAM Anterior leaflet motion; Presence of eccentric MR directed posteriorly; Presence of flow acceleration in the LVOT; Elevated LVOT velocities with late systolic peaking “dagger-shaped” Doppler envelope	ME: 4Ch, MC, 2Ch, LAX TG: deep 5Ch, LAX	<ul style="list-style-type: none"> • 2D • M-mode: MV leaflets, AV mid-systolic closure • CFD: flow acceleration location • Spectral Doppler 	<ul style="list-style-type: none"> • Dependent on preload, afterload, contractility, and heart rate after separation from CPB • SAM with central or anterior MR indicative of new MV pathology
Evaluate LV systolic function Regional wall motion (rule out possible left circumflex artery injury) Global function	ME: 4Ch, 2Ch, LAX TG: basal and mid SAX, 2Ch	<ul style="list-style-type: none"> • 2D: wall motion abnormalities • 3D: EF, SV • Spectral Doppler: LV SV 	<ul style="list-style-type: none"> • Myocardial stunning • Entrainment of air
Evaluate new/worsened AR Evaluate TR	ME: 4Ch, AV SAX/LAX, RV inflow/outflow, modified bicaval	<ul style="list-style-type: none"> • 2D, bi/multiplane imaging • CFD • 3D 	<ul style="list-style-type: none"> • Dependent on preload and afterload • Artifacts

Abbreviations: 2Ch, Two-chamber; 4Ch, four-chamber; 2D, two-dimensional; 3D, three-dimensional; AR, aortic regurgitation; CFD, color flow Doppler; CPB, cardiopulmonary bypass; EF, ejection fraction; LAX, long axis; LV, left ventricle; LVOT, left ventricular outflow tract; ME, mid-esophageal; MC, mitral commissural; MR, mitral regurgitation; MS, mitral stenosis; MV, mitral valve; MVA, mitral valve area; SAM, systolic anterior motion; SAX, short axis; SV, stroke volume; TG, transgastric; TR, tricuspid regurgitation.

the sinuses of Valsalva). After initiation of CPB, “cross-clamping” of the aorta is achieved internally by inflating the endoballoon with saline. Adequate placement of the balloon (2-4 cm above the sinuses of Valsalva)²⁰ can be verified in the ME AV LAX view. CFD can be used to confirm the absence of flow around the balloon, and therefore complete occlusion of the aorta. During CPB, periodically, the position of the balloon should be monitored as the balloon may migrate either proximally into the aortic root or distally into the aortic arch. CFD can also be applied in the ME AV LAX view during delivery of antegrade cardioplegia into the aortic root (Figure 3A).

A coronary sinus (CS) catheter for retrograde cardioplegia is placed through the right internal jugular vein into the RA and into the CS (Figure 3B). The three lumens of the CS catheter permit balloon inflation, cardioplegia delivery, and coronary sinus pressure measurement. The CS can be visualized in long axis either in the ME modified bicaval view or in the deep ME 4Ch view. While practice may vary, generally the CS catheter can be seen engaging the CS ostium in the ME modified bicaval view and it can be advanced into the CS using the deep ME 4Ch view while turning the probe slightly to the left in order to follow the CS along its path in the posterior AV groove. All efforts should be made to visualize the inflated CS catheter balloon in the CS in order to ensure adequate positioning of the tip. While on CPB, delivery of cardioplegia in the CS and absence of flow around the CS catheter balloon can be confirmed in the deep ME 4Ch view. A combination of TEE guidance and fluoroscopy has been

used for the placement and advancement of the CS catheter,²⁰ however successful and safe placement and management of the CS catheter solely using TEE has been reported²¹ and avoids potential contamination of the surgical field by the fluoroscopy equipment as well as radiation exposure. As retrograde cardioplegia delivery will not be efficient in the presence of a PLSVC, this anomaly should be excluded prior to placement of a percutaneous CS catheter. In most cases, a PLSVC empties into the RA through a dilated CS. The PLSVC can be seen as an echo-lucent space between the LAA and the left upper pulmonary vein, in lieu of the ligament of Marshall. Also, a dilated CS, with early filling of agitated saline after injection into the left upper extremity venous circulation, is consistent with PLSVC.

3.1.5. Postprocedure Assessment. Mitral Valve Repair.—Prior to evaluation of MV repair it is imperative to understand the type of repair performed by the surgeon, as the surgical technique will influence the echocardiographic findings. A quick assessment of the adequacy of MV repair can be performed as soon as the aortic cross-clamp is released, the heart is contracting, and the LV is at least partially volume loaded. Communication with the surgeon prior to final separation from CPB to review potentially problematic areas of repair is important so that further interventions may be attempted prior to weaning off of CPB. However, comprehensive evaluation of the adequacy of repair should be performed after complete

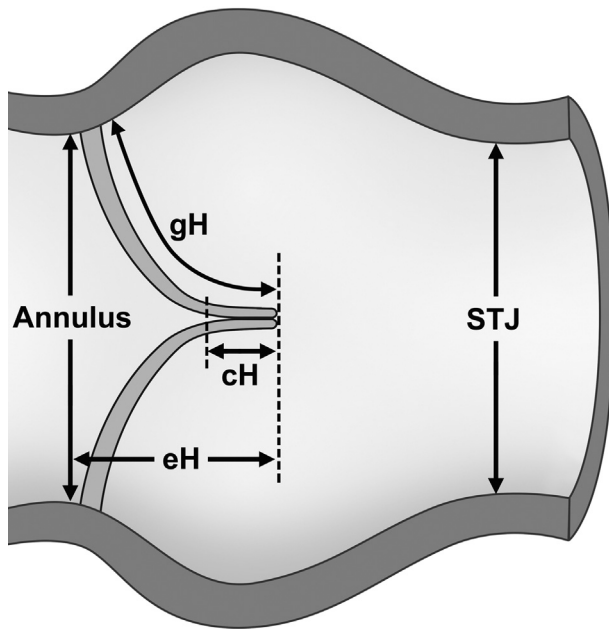


Figure 4 Echocardiographic measurements of the aortic root performed in the preprocedure assessment for aortic valve repair. Abbreviations: *cH*, Coaptation height; *eH*, effective height; *gH*, geometric height of the aortic valve cusps, *STJ*, sinotubular junction. Redrawn from Berrebi A, Monin JL, and Lansac E, Systematic echocardiographic assessment of aortic regurgitation-what should the surgeon know for aortic valve repair? *Ann Cardiothorac Surg* 2019; 8:331-341.

separation from CPB and under adequate loading conditions. Assessment of MV repair includes characterization of: (1) residual MR, (2) iatrogenic MS, (3) SAM, (4) LV function, and (5) iatrogenic aortic regurgitation (AR).

A successfully repaired MV should have no more than mild MR immediately after separation from CPB. Volume and afterload challenges should be undertaken to simulate baseline physiologic conditions and avoid underestimation of residual MV pathology. The echocardiographic principles for evaluation of residual MR are similar to those for native valves.² The presence of greater than mild MR should prompt further investigation to determine the mechanism of post-repair MR and help guide re-repair or replacement.

Flow acceleration seen by CFD on the atrial side of the repaired MV should raise the suspicion of iatrogenic MS. Evaluation for iatrogenic MS after MV repair should include measurement of pressure gradients and direct measurement or calculation of the MV area. The criteria for MS include a mean gradient more than 6 mm Hg and a MV area less than 1.8 cm².²² Caution must be exercised in the presence of a number of factors, which can influence transmitral flow and therefore transmitral gradient, such as atrial fibrillation, tachycardia, high or low cardiac output. Of note, Doppler interrogation of a MV repair with an edge-to-edge suture (Alfieri stitch) resulting in a double-orifice valve can be performed through either orifice, as the difference in mean pressure gradient between the two orifices is not clinically relevant.²³ Controversy exists as to whether pressure half-time (PHT) is accurate for the calculation of the repaired MV area.²² MV area measurement by multiplanar reconstruction of a 3D data set may account for the geometric anatomical distortion post repair and correlates well with other measures of MS severity.²⁴ As all these measurements must be interpreted contextually within

the given clinical circumstances, it is important to perform them when the patient is hemodynamically optimized and to report them along with hemodynamic data.

SAM of the MV is a known complication following MV repair, with a reported incidence of 1-16%.²⁵ SAM associated with obstruction of the LVOT and posteriorly oriented MR in the presence of optimized preload, afterload, and heart rate may warrant re-repair. The decision to re-repair depends on patient factors, echocardiographic assessment, and surgical technique.

The presence of prosthetic material (annuloplasty ring, neochords, leaflet augmentation) may not allow a complete examination of the repaired MV leaflets or other subvalvular structures at the ME level; therefore TG views may be necessary.

The evaluation should be completed with a comprehensive examination of LV function. LV volume should be optimized, and regional wall motion abnormalities should be ruled out, as the circumflex coronary artery can be compromised during suturing of an annuloplasty ring or prosthetic valve.

Mitral Valve Replacement.—Assessment of prosthetic valves in the mitral position by 2D, 3D, and Doppler echocardiography has been comprehensively described in published guidelines.²⁶ The intraoperative environment provides unique challenges for the assessment of prosthetic valves due to possible acute and frequent changes in hemodynamic status. A prosthetic valve in the mitral position should be inspected for (1) adequate functioning of the mechanical disks or bioprosthetic leaflets, and (2) the presence of intra- or paravalvular pathological regurgitation. Adequate motion of the prosthetic valve disks/leaflets can be examined after removal of the aortic cross-clamp. Excursion of the prosthetic valve disks/leaflets may be limited by interposition of subvalvular tissue, or in the presence of low flow across the valve in a partially filled LV. Comprehensive evaluation of the prosthetic valve should be performed after complete separation from CPB, and in conditions of optimized preload, afterload, contractility, and heart rate. The entire sewing ring of the mitral prosthesis should be imaged at the ME level by sweeping the multiplane angle from 0° to 180° while keeping the prosthetic valve in the center of the image. Off-axis and non-standard views, in conjunction with withdrawing/advancing and right/left rotation of the TEE probe, are sometimes required. CFD should be used to locate abnormal intra- and para-prosthetic flow. The normal “washing” jets of mechanical prosthetic valves should be identified and differentiated from pathological regurgitation. By providing en face views of the mitral valve, 3D echocardiography (with and without CFD) can evaluate the location and characteristics of the paravalvular regurgitation more precisely. Immobile leaflets in the presence of adequate loading conditions, and moderate or severe paravalvular leaks, should trigger surgical intervention, while the management of a mild paravalvular leak is controversial because it often runs a benign course.^{27,28} The decision for immediate correction requires a team approach, should be tailored to each patient and clinical situation, and weighed against the risk of prolonged surgery.

Key points regarding postprocedure assessment for MV surgery are presented in Table 3.

3.2. Aortic Valve

3.2.1. Preprocedure Assessment. Recent published guidelines⁸ have described the recommended imaging planes for visualizing the AV. Pre-CPB imaging should focus on assessment of valve

Table 4 Key points for the pre-surgical assessment for aortic valve surgery

Imaging goals	Imaging views	Imaging modalities	Limitations
Evaluate AV anatomy Cusps morphology and motion Coaptation length/height; Masses (endocarditis, pitfalls: Lambl's excrescences, Arantius nodules, fibroelastomas)	ME: AV SAX, LAX TG: deep 5Ch, LAX	<ul style="list-style-type: none"> • 2D, bi/multiplane imaging • 3D: cusp coaptation height, LVOT diameter/area • Aortic annulus diameter/area • AVA planimetry 	<ul style="list-style-type: none"> • 2D: off-axis measurements • 3D: spatial/temporal resolution, acquisition artifacts, post-processing requirements
Identify coronary arteries ostia	ME: AV SAX, LAX	<ul style="list-style-type: none"> • 2D, bi/multiplane imaging • CFD • Spectral Doppler (diastolic predominance) • 3D 	<ul style="list-style-type: none"> • 2D: acoustic shadowing • 3D: spatial/temporal resolution, post-processing required
Evaluate AV function Aortic stenosis: AV peak velocity and mean pressure gradient; AVA (planimetry and continuity equation) Aortic regurgitation: AR jet(s) origin and direction, vena contracta, PHT; Descending aorta: diastolic flow reversal	ME: AV SAX, LAX TG: deep 5Ch, 2Ch, LAX Descending aorta: SAX, LAX	<ul style="list-style-type: none"> • 2D (planimetry AVA) • M-mode: AV cusp excursion • CFD: flow acceleration: sub-, intra- and supra-valvular fixed vs dynamic • CFD: AR vena contracta • Spectral Doppler: velocity profiles, AVA by continuity, holodiastolic flow reversal • 3D (AVA planimetry) • 3D with/out CFD: AR jets and direction 	<ul style="list-style-type: none"> • Loading conditions • LV function • LV compliance • Aortic compliance • Co-existent valvular lesions • Erroneous LVOT diameter measurements • Misalignment of Doppler beam • Presence of artifacts
Associated lesions MV: presence of MR Asymmetric septal hypertrophy, presence of SAM	ME: 4/5Ch, MC, 2Ch, LAX	<ul style="list-style-type: none"> • 2D • CFD • M-mode: premature systolic closure, MV anterior leaflet fluttering, presence of diastolic MR 	<ul style="list-style-type: none"> • Loading conditions • LV function
Evaluate LV function Regional and global systolic function	ME: 4Ch, 2Ch, LAX TG: basal SAX, mid SAX, 2Ch, deep 5Ch	<ul style="list-style-type: none"> • 2D: qualitative wall motion • 2D: method of disks • 3D: volumetric analysis • Spectral Doppler: LVOT SV 	<ul style="list-style-type: none"> • 2D: geometric assumptions • 3D: spatial/temporal resolution; postprocessing requirements

Abbreviations: 2Ch, Two-chamber; 4Ch, four-chamber; 5Ch, five-chamber; 2D, two-dimensional; 3D, three-dimensional; AR, aortic regurgitation; AV, aortic valve; AVA, aortic valve area; CFD, color flow Doppler; LAX, long axis; LV, left ventricle; LVOT, left ventricular outflow tract; ME, mid-esophageal; MC, mitral commissural; MR, mitral regurgitation; MV, mitral valve; PHT, pressure half-time; SAM, systolic anterior motion; SAX, short axis; SV, stroke volume; TG, transgastric.

morphology, number and appearance of cusps, and length of each cusp free edge. The normal AV cusps coapt in diastole above the annular plane in the mid portion of the sinuses of Valsalva, resulting in a coaptation height (Figure 4) of 1-2 mm in the ME AV LAX view. Poor cusp coaptation related to cusp prolapse or central malcoaptation can be identified in this view. Surrounding structures should also be evaluated; for example, the presence of calcium may extend to the LVOT, aortic annulus, MV, and aortic walls and may complicate AV replacement surgery. Measurements of the LVOT and aortic annulus diameters should be made in early to mid-systole in the ME AV LAX view. These measurements may represent the minor diameter of these structures in patients with an elliptical LVOT/aortic annulus.⁹ The aortic annulus should be measured inner edge to inner edge from the hinge point of the right coronary cusp to the posterior "virtual annulus" at the level of the commissure between the left and noncoronary cusps.⁹ Some investigators recommend measuring the LVOT diameter at the level of the aortic annulus, rather than immediately underneath the aortic annulus, as the latter mea-

surement may underestimate aortic valve area (AVA) by the continuity equation in patients with a sigmoid septum.²⁹⁻³¹

Application of CFD can localize the presence of systolic flow acceleration and obstruction in the LVOT, AV, and proximal ascending aorta. In diastole, CFD can be used to detect AR and localize the regurgitant orifice by performing small adjustments of the TEE probe depth, rotation, and multiplane angle. Flow in the right and left main coronary arteries may also be imaged by CFD.

Evaluation of transaortic flow and peak velocities, measurement of forward stroke volume, and calculation of AVA using the continuity equation with spectral Doppler interrogation should be performed in the TG views, which enable alignment of transaortic flow parallel to the insonation beam. The assessment of AR jets may also be performed from these views, using CFD to guide better alignment of the Doppler beam with the AR jet.

Acquisition of 3D data sets from either the ME AV SAX or AV LAX views by using a narrow, zoomed volume provides superior spatial and temporal resolution of the AV and LVOT. Multiplanar

Table 5 Key points for the post-surgical assessment for aortic valve surgery

Imaging goals	Imaging views	Imaging modalities	Limitations
Evaluation of AVR/repair following aortic cross-clamp release: Residual/new AR (jet characteristics); LV de-airing	ME: AV SAX, LAX	<ul style="list-style-type: none"> • 2D • CFD 	<ul style="list-style-type: none"> • Loading conditions • Far-field acoustic shadowing
Evaluation of AVR following weaning off CPB Intra/paravalvular AR; Motion of prosthetic leaflets; Peak velocity/mean gradient, DVI; Effective orifice area (continuity equation)	ME: AV SAX, LAX TG: deep 5Ch, 2Ch, LAX	<ul style="list-style-type: none"> • 2D, bi/multiplane imaging • CFD • Spectral Doppler • 3D 	<ul style="list-style-type: none"> • Loading conditions • Artifacts • Doppler misalignment
Evaluation of AV repair Presence/severity of AR; Coaptation height Transvalvular mean pressure gradient	ME: AV SAX, LAX TG: deep 5Ch, LAX	<ul style="list-style-type: none"> • 2D: AVA planimetry • CFD • 3D: AVA planimetry • Spectral Doppler 	<ul style="list-style-type: none"> • Loading conditions • Artifacts • 3D post-processing requirement • Doppler misalignment
Evaluation of LV function Systolic function: global/regional	ME: 4Ch, 2Ch, LAX TG: basal SAX, mid SAX, 2Ch, deep 5Ch	<ul style="list-style-type: none"> • 2D: qualitative wall motion • 2D: method of disks • 3D: volumetric analysis 	<ul style="list-style-type: none"> • 2D: geometric assumptions • 3D: spatial/temporal resolution, postprocessing requirements
Rule out coronary arteries ostia injury: Identify coronary artery ostial injury New wall motion abnormalities	ME: AV SAX, LAX	<ul style="list-style-type: none"> • 2D, bi/multiplane imaging • CFD • 3D 	<ul style="list-style-type: none"> • 3D: lower spatial resolution, post-processing required

Abbreviations: 2Ch, Two-chamber; 4Ch, four-chamber; 5Ch, five-chamber; 2D, two-dimensional; 3D, three-dimensional; AR, aortic regurgitation; AV, aortic valve; AVA, aortic valve area; AVR, aortic valve replacement; CFD, color flow Doppler; CPB, cardiopulmonary bypass; DVI, Doppler velocity index; LAX, long axis; LV, left ventricle; LVOT, left ventricular outflow tract; ME, mid-esophageal; SAM, systolic anterior motion; SAX, short axis; SV, stroke volume; TAPSE, tricuspid annular plane systolic excursion; TG, transgastric.

reconstruction of a 3D data set enables measurement of diameter, area and perimeter of the AV annulus and LVOT area, as well as inter-commissural distance, free-margin cusp length, and cusp coaptation.² These measurements can be used to determine prosthetic valve size³² and graft size in valve-sparing root surgery.³³

3.2.2. Evaluation of Specific AV Pathologies. Aortic Stenosis.—Doppler assessment of severity should complement examination of valve morphology by 2D or 3D TEE. Flow-dependent and flow-independent Doppler measurements are used to evaluate the severity of aortic stenosis (AS).³ Velocity and pressure gradients are dependent on flow and anatomic valve area; therefore, it is paramount to calculate LV stroke volume when interpreting Doppler measurements. Additionally, adequate cardiac output in an individual is dependent on body size, and indexing the AVA to body surface area (BSA) can help determine lesion severity; indexing the valve area is particularly important in smaller patients with height <135 cm, BSA <1.5 m², or body mass index <22 kg/m².³ The ACC guidelines use an indexed AVA of <0.6 cm²/m² to define severe AS.³⁴ For similar reasons, the presence of significant AR, MR,

or a hyperdynamic LV should be considered when interpreting Doppler measurements. Low gradients may occur in the presence of a severely reduced AVA if the flow across the valve is reduced (e.g., significant MR or reduced LV function). In these instances, relatively flow-independent measurements, such as AVA and velocity ratio, are recommended to establish AS severity.³ Of note, due to changes in cardiac loading conditions under general anesthesia, intraoperative measurements of transvalvular velocities and gradients are often lower when compared with preoperative measurements by TTE, whereas measurements of velocity ratio seem to be more concordant with TTE counterparts.³⁵

Aortic Regurgitation.—Current ASE guidelines² advocate integration of a multi-window, multiple-parameter (qualitative, semi-quantitative, quantitative) approach to evaluate AR.

Quantitative assessment of regurgitant volumes, regurgitant fraction, and effective regurgitant orifice area (EROA) are challenging to perform in the operating room, given that these time-consuming measurements may be impractical in a setting with limited time to perform a comprehensive exam.

Table 6 Key points for the pre- and postprocedure assessment for tricuspid valve surgery

Imaging goals	Imaging views	Imaging modalities	Limitations
PREPROCEDURE			
Evaluate TV anatomy: Leaflet appearance; Leaflet tethering; Tricuspid annulus	ME: 4/5Ch, RV inflow/ outflow, modified bicaval TG: RV basal, RV inflow	<ul style="list-style-type: none"> • 2D, bi/multiplane imaging • 3D 	<ul style="list-style-type: none"> • Far-field position of the valve • Variability in anatomy
Evaluate TR: Number/direction of jets; Vena contracta width/area; RVSP	ME: 4/5Ch, RV inflow/ outflow, modified bicaval TG: RV inflow/outflow	<ul style="list-style-type: none"> • 2D, bi/multiplane imaging • CFD: TR jet orientation • CW Doppler: TR jet • PW Doppler: transtricuspid E velocity 	<ul style="list-style-type: none"> • Need for multiple views • Variable geometry of the regurgitant orifice • Doppler misalignment
Measure TA	ME 4Ch	<ul style="list-style-type: none"> • 2D • 3D 	<ul style="list-style-type: none"> • Variable geometry of the TA • Nonstandardized views for measurements
Evaluate TS: Mean pressure gradient	ME: 4/5Ch, RV inflow/ outflow, modified bicaval	<ul style="list-style-type: none"> • 2D • CFD • Spectral Doppler 	<ul style="list-style-type: none"> • Co-existent valvular lesions
Neighboring structures: Coronary sinus, RA appendage, venae cavae, hepatic veins, IAS	ME: 4 Ch, bicaval (IVC, SVC), Ascending aorta SAX (SVC)	<ul style="list-style-type: none"> • 2D, bi/multiplane imaging • CFD • Spectral Doppler: HVF profile 	
Evaluate RV/RA size and function Systolic and diastolic motion of IAS and IVS	ME: 4/5 Ch, RV inflow/ outflow TG: mid SAX, RV inflow/ outflow	<ul style="list-style-type: none"> • 2D, bi/multiplane imaging • CFD • Spectral Doppler 	<ul style="list-style-type: none"> • Need for multiple views • Complex RV geometry
POSTPROCEDURE			
Morphology/anatomy	ME: 4/5Ch, RV inflow/ outflow, modified bicaval	<ul style="list-style-type: none"> • 2D, bi/multiplane imaging • 3D 	<ul style="list-style-type: none"> • Acoustic shadowing from prosthetic material
Residual TR	TG: RV inflow/outflow, RV inflow	<ul style="list-style-type: none"> • CFD • Spectral Doppler 	<ul style="list-style-type: none"> • Affected by loading conditions and inotropy
Exclude iatrogenic TS			<ul style="list-style-type: none"> • Doppler misalignment

Abbreviations: 2Ch, Two-chamber; 4Ch, four-chamber; 5Ch, five-chamber; 2D, two-dimensional; 3D, three-dimensional; CFD, color flow Doppler; CW, continuous-wave; E, early diastolic filling; IAS, interatrial septum; IVC, inferior vena cava; IVS, interventricular septum; LAX, long axis; ME, mid-esophageal; PW, pulsed-wave; RA, right atrium; RV, right ventricle; SAX, short axis; SVC, superior vena cava; TA, tricuspid annulus; TAPSE, tricuspid annular plane systolic excursion; TG, transgastric; TR, tricuspid regurgitation; TS, tricuspid stenosis; TV, tricuspid valve.

More recently, AV repair has proven to be both feasible and durable in selected patients with AR, therefore avoiding the risks associated with prosthetic valves.³⁶⁻³⁸ First and foremost, evaluating and understanding the mechanism of AR³⁹ enables adequate choice of repair techniques for each valve lesion⁴⁰ and has been proven effective in predicting the primary repair technique.³⁹

Intra-operative 2D and 3D TEE can (1) define the mechanism of AR, (2) provide information to guide the repair, (3) interrogate the result, and (4) determine the predictors of durability.⁴¹⁻⁴³ In addition to the standard 2D and CFD assessment of the AV as described above, the pre-AV repair TEE focuses on aortic root measurements, aortic cusp motion, level of cusp coaptation, coaptation height, and analysis of the AR jet direction (Figure 4).⁴¹ Simultaneous multiplane imaging allows scanning of the cusp edge and more precise localization of lesions, particularly useful in differentiating between non-coronary and left coronary pathology.

3.2.3. Assessment of Associated Lesions. Mitral Valve Disease.—Patients with AS may have concomitant MV and TV disease. The assessment of MR severity uses similar methods as outlined in

section 3.1.2. Typically, MR severity is trivial or mild, but may be moderate or severe in up to 20% of patients.⁴⁴ While functional MR significantly improves after aortic valve replacement in up to 60% of patients, MR persists and may be associated with higher morbidity in some patients.^{44,45} Calcific degeneration of the mitral valve, atrial fibrillation, large left atrial size (>5 cm), pulmonary hypertension, and mitral valve tenting area >1.4 cm² have been identified as independent risk factors for persistent MR.⁴⁶⁻⁴⁸ The morbidity of double valve replacement is substantially higher than that for isolated aortic valve replacement (AVR). Conversely, reoperation for MV disease after AVR is technically more challenging as surgical access and exposure of the MV is more difficult. Patient and surgical factors should be taken into consideration before deciding to operate on a second valve.

Septal Myectomy.—In a patient presenting with AS, concentric left ventricular hypertrophy (LVH) is a compensatory mechanism related to flow restriction and systolic pressure overload that minimizes LV systolic wall stress. With aging, the ascending aorta dilates, thereby altering its relationship with the LV, becoming more sharply angled.

Table 7 Key points for the pre- and postprocedure assessment for pulmonic valve surgery

Imaging goals	Imaging views	Imaging modalities	Limitations
PREPROCEDURE			
PV anatomy PV leaflet morphology and motion; PV annulus dimensions; Sub- or supra-annular stenosis	ME: RV inflow/outflow, ascending aorta SAX/LAX UE: aortic arch SAX TG: RV basal, RV inflow/outflow	<ul style="list-style-type: none"> • 2D, bi/multiplane imaging • CFD • 3D 	<ul style="list-style-type: none"> • Poor echogenicity (anterior location, thin leaflets) • Acoustic shadowing from aortic root • Difficult to exclude perforations, fenestrations
PV function Evaluate PR: PHT, PA flow reversal; Jet width: pulmonary annulus ratio Evaluate PS: Peak velocity Peak pressure gradient	UE: aortic arch SAX ME: RV inflow/outflow TG: RV basal, RV inflow/outflow	<ul style="list-style-type: none"> • CFD • Spectral Doppler 	<ul style="list-style-type: none"> • Affected by loading conditions • Doppler misalignment
Noninvasive hemodynamics SPAP Mean PAP Mid-systolic notching of RVOT Doppler envelope; PVR ($TR_{jet}/VTI_{RVOT} \times 10$) PA acceleration time RVOT stroke volume	UE: aortic arch SAX ME: RV inflow/outflow TG: RV basal, RV inflow/outflow	<ul style="list-style-type: none"> • CFD • Spectral Doppler 	<ul style="list-style-type: none"> • Affected by loading conditions • Doppler misalignment
POSTPROCEDURE			
Morphology/anatomy Residual PR Sub-valvular stenosis Exclude iatrogenic PS	UE: aortic arch SAX ME: RV inflow/outflow, ascending aorta SAX TG: RV basal, RV inflow/outflow	<ul style="list-style-type: none"> • 2D, biplane imaging • CFD • 3D • Spectral Doppler 	<ul style="list-style-type: none"> • Poor echogenicity • Artifacts • Affected by loading conditions • Doppler misalignment

Abbreviations: 2Ch, Two-chamber; 4Ch, four-chamber; 5Ch, five-chamber; 2D, two-dimensional; 3D, three-dimensional; CFD, color flow Doppler; DPAP, diastolic pulmonary artery pressure; LAX, long-axis; ME, mid-esophageal; PA, pulmonary artery, PHT, pressure half-time; PR, pulmonic valve regurgitation, PS, pulmonic valve stenosis, PV, pulmonic valve; PVR, pulmonary vascular resistance; RA, right atrium; RV, right ventricle; RVOT, right ventricle outflow tract; SAX, short-axis; SPAP, systolic pulmonary artery pressure; SV, stroke volume; TG, transgastric; TR, tricuspid regurgitation; UE, upper esophageal; VTI, velocity-time integral.

A discrete bulge (<3 cm length) of the basal interventricular septum into the LVOT results in a sigmoid-shaped septum, which may result in dynamic subaortic obstruction after AVR. A small (LV end-diastolic diameter <42 mm), hyperdynamic, and asymmetrically hypertrophied LV (IVS/posterior wall >1.45) have been identified as independent predictors of abnormal subvalvular flow after AVR.⁴⁹ Septal myectomy concomitant with the AVR could be considered in these patients.

Key points of preprocedure assessment for AV surgery are presented in Table 4.

3.2.4. Postprocedure Assessment. It is possible to detect new or residual AR following root pressurization after aortic cross-clamp

removal. Acoustic shadowing may limit assessment in ME views, and TG imaging may be challenging in a partially filled LV. Following separation from CPB and after optimization of hemodynamic conditions, TEE assessment of AV intervention (repair or replacement) should focus on detecting and determining AR severity, and examining the morphology and function of the repaired or prosthetic AV.

Aortic Valve Repair.—Systematic evaluation of the AV after repair is mandatory. The following steps in assessment of AV repair are recommended:

- (1) A successfully repaired AV has no or minimal residual AR by interrogation with CFD. The presence of greater than mild AR, especially if eccentric,

Table 8 Key points for the pre- and postprocedure assessment in coronary artery bypass graft surgery

Imaging goals	Imaging views	Imaging modalities	Limitations
LV anatomy: Shape and size (regional and global), wall thickness	ME: 4/5Ch, 2Ch, LAX TG: basal SAX, mid SAX, 2Ch	<ul style="list-style-type: none"> • 2D, bi/multiplane imaging • M-mode • 3D 	<ul style="list-style-type: none"> • LV foreshortening • M-mode: evaluation only of anterior and inferior segments • 3D: low spatial/temporal resolution, post-processing requirements
Global LV function ED and ES areas ED and ES volumes SV EF	ME: 4/5Ch, 2Ch, LAX TG: basal SAX, mid SAX, 2Ch	<ul style="list-style-type: none"> • 2D: method of disks, FAC • M-mode: MAPSE, FS • Spectral Doppler: SV, MPI • Tissue Doppler: S', MPI • 3D • Speckle tracking 	<ul style="list-style-type: none"> • Geometric assumptions • Affected by loading conditions • Doppler misalignment • 3D: low spatial/temporal resolution
Regional LV function Wall motion and thickening	ME: 4/5Ch, 2Ch, LAX TG: basal SAX, mid SAX, 2Ch	<ul style="list-style-type: none"> • 2D bi/multiplane imaging • M-mode • Tissue Doppler • Speckle tracking 	<ul style="list-style-type: none"> • 2D: observer dependent • Doppler misalignment • Speckle tracking: time consuming (noisy signal, post-processing) • Affected by loading conditions
Diastolic function	ME: 4/5Ch, 2Ch, LAX	<ul style="list-style-type: none"> • Spectral Doppler: transmitral flow, pulmonary vein flow • Tissue Doppler: mitral annulus velocities, E/e' 	<ul style="list-style-type: none"> • Doppler misalignment • Affected by loading conditions • Affected by co-existent valvular disease • Affected by heart rate and rhythm
Aortic atheromatous disease Postprocedure: evaluate for iatrogenic dissection	ME: ascending aorta SAX/ LAX UE: aortic arch SAX/LAX Descending aorta views Epi-aortic scanning	<ul style="list-style-type: none"> • 2D • 3D 	<ul style="list-style-type: none"> • "Blind spot" distal ascending aorta and aortic arch • Near-field artifacts

Abbreviations: 2Ch, Two-chamber; 4Ch, four-chamber; 5Ch, five-chamber; 2D, two-dimensional; 3D, three-dimensional; CFD, color flow Doppler; E, transmitral flow peak early filling velocity, e' tissue Doppler mitral annulus peak early diastolic myocardial velocity; ED, end-diastolic; EF, ejection fraction; ES, end-systolic; FAC, fractional area change; FS, fractional shortening; LAX, long axis; LV, left ventricle; ME, mid-esophageal; MPI, myocardial performance index; SAX, short axis; SV, stroke volume; TG, transgastric; UE, upper esophageal.

should prompt further investigation to determine the mechanism of post-repair AR and help guide re-repair or possible valve replacement. The valve interrogation should take into account the type of repair. For example, excessive reduction in annular dimensions in a patient with a dilated aortic annulus and type I AR may result in excess leaflet tissue and subsequent type II AR due to cusp prolapse.

- (2) The level of cusp coaptation should be at or above the aortic annulus in the ME AV LAX view. An effective height (distance from the aortic annulus to the leaflet tips; Figure 4) greater than 9 mm is associated with a high probability of normal or near normal AV function. Conversely, in patients with cusp coaptation below the annular level, the risk of subsequent significant AR can be as high as 71%.^{41,50}
- (3) The cusp coaptation height (Figure 4) should be >4 mm as measured in the ME AV LAX view. The likelihood of moderate or severe AR at long-term follow-up is minimal when coaptation height is ≥4 mm, even when mild AR has been identified in the early postoperative exam.⁵¹
- (4) A large aortic annulus post repair has also been associated with a high failure rate. It is recommended that the aortic annulus diameter post repair should be less than 25 mm.^{41,51}
- (5) The post-repair mean transvalvular pressure gradient should be less than 10 mm Hg.⁴¹

Aortic Valve Replacement.—Assessment of prosthetic valves in the aortic position follows the published ASE recommendations²⁶ and should include (1) identification of the sewing ring and evaluation of proper functioning of the valve leaflets; (2) exclusion of the pres-

ence of pathological regurgitation (intra- or paravalvular); and (3) establishment of the hemodynamic profile of the newly implanted valve. Evaluation of prosthetic valves in the aortic position includes several views at the ME and TG levels. In the TG views, reverberation and shadowing artifacts caused by the prosthetic material are located distal to the AV and LVOT, thereby enabling evaluation of AR by CFD. The entire circumference of the sewing ring can be visualized in the short-axis orientation at the ME level. However, in each particular view, subtle probe manipulation is required to ensure precise imaging at the level of the sewing ring; biplane or multiplane imaging can be useful.

The measured gradients of an aortic valve prosthesis depend on ventricular contractility, loading conditions, and type, size, and location of the prosthesis.

Immediately following implantation, the prosthetic valve should be evaluated for pathological regurgitation. Intravalvular regurgitation is a common finding in normally functioning bioprosthetic valves (10%) and is often seen as a small central or commissural jet. Mechanical valves have specific patterns of washing jets that minimize blood stasis in the hinge mechanism, preventing thrombus formation. These washing jets are seen within the sewing ring, occur early during valve closure, and are of short duration and length. Simultaneous multiplane imaging permits easier identification and characterization of these jets. Regurgitant jet features that may suggest more than mild regurgitation include wide jet

Table 9 Key points for the preprocedure assessment in aortic surgery

Imaging goals	Imaging views	Imaging modalities	Limitations
Ascending aorta: LVOT, AV, sinotubular junction, ascending aorta Aortic arch (including great vessels) Descending aorta	ME: ascending aorta LAX, SAX UE: aortic arch SAX, LAX Descending aorta: SAX, LAX	<ul style="list-style-type: none"> • 2D, bi/multiplane imaging • CFD • Spectral Doppler • 3D 	<ul style="list-style-type: none"> • “Blind spot” distal ascending aorta and aortic arch • Off axis measurements
Atheromatous disease: Location Measurements Mobile/ulcerated lesions	ME: ascending aorta LAX, SAX UE: aortic arch SAX, LAX Descending aorta: SAX, LAX	<ul style="list-style-type: none"> • 2D, bi/multiplane imaging • 3D 	<ul style="list-style-type: none"> • “Blind spot” distal ascending aorta and proximal aortic arch • Near-field artifacts • Observer dependent • Not accounting for “atheroma burden”
Aortic dissection: Dissection flap, entry tear, extension, false vs true lumen Coronary arteries involvement Wall motion abnormalities Aortic regurgitation Pericardial effusion Pleural effusion Other acute aortic syndromes: Penetrating ulcer Intramural hematoma	ME: ascending aorta LAX, SAX UE: aortic arch SAX, LAX ME: AV SAX, LAX (AR, coronary arteries involvement)	<ul style="list-style-type: none"> • 2D, bi/multiplane imaging • CFD: entry tear, AR evaluation, coronary arteries involvement • M-mode: systolic expansion of true lumen • Spectral Doppler: systolic flow in true lumen 	<ul style="list-style-type: none"> • “Blind spot” distal ascending aorta and proximal aortic arch • Artifacts (mirror image, reverberations)
Aortic aneurysm: Location Aortic regurgitation	ME: ascending aorta LAX, SAX UE: aortic arch SAX, LAX ME: AV SAX, LAX	<ul style="list-style-type: none"> • 2D, bi/multiplane imaging • CFD: AR 	<ul style="list-style-type: none"> • “Blind spot” distal ascending aorta and proximal aortic arch

Abbreviations: 2D, Two-dimensional; 3D, three-dimensional; AR, aortic regurgitation; AV, aortic valve; CFD, color flow Doppler; LAX, long axis; LVOT, left ventricular outflow tract; ME, mid-esophageal; SAX, short axis; SV, stroke volume; TG, transgastric; UE, upper esophageal.

Table 10 Key points for the postprocedure assessment in aortic surgery

Imaging goals	Imaging views	Imaging modalities	Limitations
Evaluation of AV repair Residual AR Coaptation height Transvalvular pressure gradient	ME: AV SAX, AV LAX TG: deep 5Ch, LAX	<ul style="list-style-type: none"> • 2D, bi/multiplane imaging • CFD • Spectral Doppler • 3D 	<ul style="list-style-type: none"> • Acoustic artifacts • Loading conditions • Doppler misalignment
Evaluation of AV replacement Intra/paravalvular AR Motion of leaflets/disks Pressure gradients			
Evaluation of coronary arteries reimplantation Reimplanted coronaries flow Wall motion abnormalities	ME: ascending aorta LAX, SAX, 4Ch, 2Ch, LAX TG: basal SAX, mid SAX, 2Ch	<ul style="list-style-type: none"> • 2D, bi/multiplane imaging • CFD 	<ul style="list-style-type: none"> • Acoustic artifacts • Loading conditions
Evaluation of endovascular procedures Correct placement of guidewires Endoleaks Iatrogenic aortic dissection	ME: ascending aorta LAX, SAX UE: aortic arch SAX, LAX ME: AV SAX, LAX Descending aorta SAX LAX	<ul style="list-style-type: none"> • 2D, bi/multiplane imaging • CFD • M-mode: True vs false lumen • Spectral Doppler: systolic flow in true lumen 	<ul style="list-style-type: none"> • “Blind spot” distal ascending aorta and proximal aortic arch • Artifacts (mirror image, reverberations) • Acoustic shadowing from the deployed stent

Abbreviations: 2D, Two-dimensional; 3D, three-dimensional; AR, aortic regurgitation; AV, aortic valve; CFD, color flow Doppler; LAX, long axis; ME, mid-esophageal; SAX, short axis; SV, stroke volume; TG, transgastric; UE, upper esophageal.

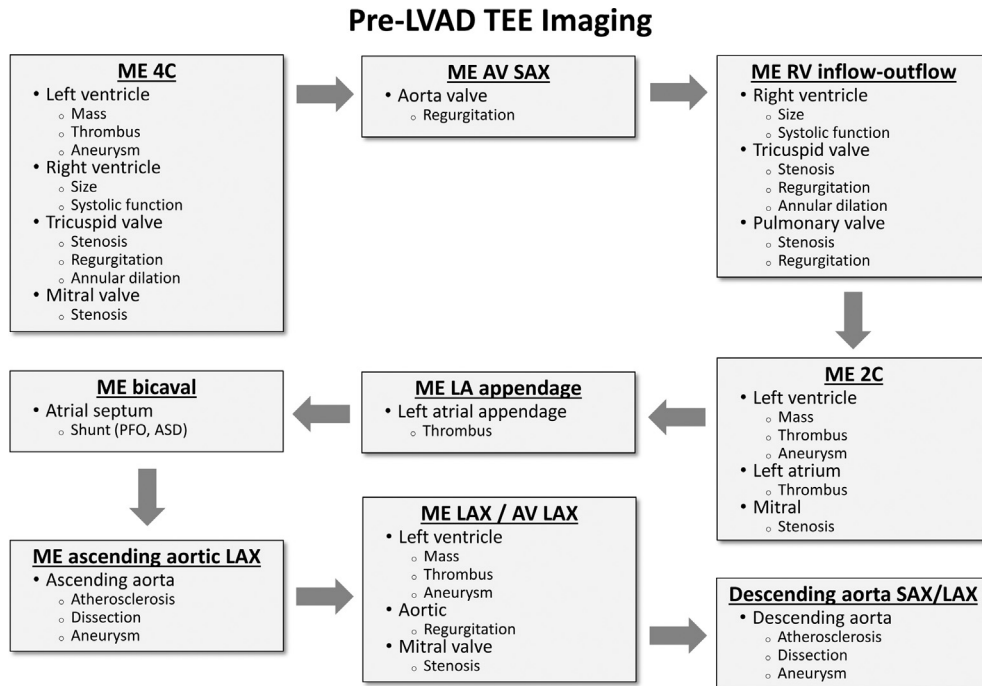


Figure 5 Proposed imaging strategy starting from the ME 4-chamber view, prior to implantation of a left ventricular assist device (LVAD). Abbreviations: 2C, Two-chamber; 4C, four-chamber; ASD, atrial septal defect, AV, aortic valve; LA, left atrium; LAX, long-axis; ME, mid-esophageal; PFO, patent foramen ovale; RV, right ventricle; SAX, short-axis; TEE, transesophageal echocardiography.

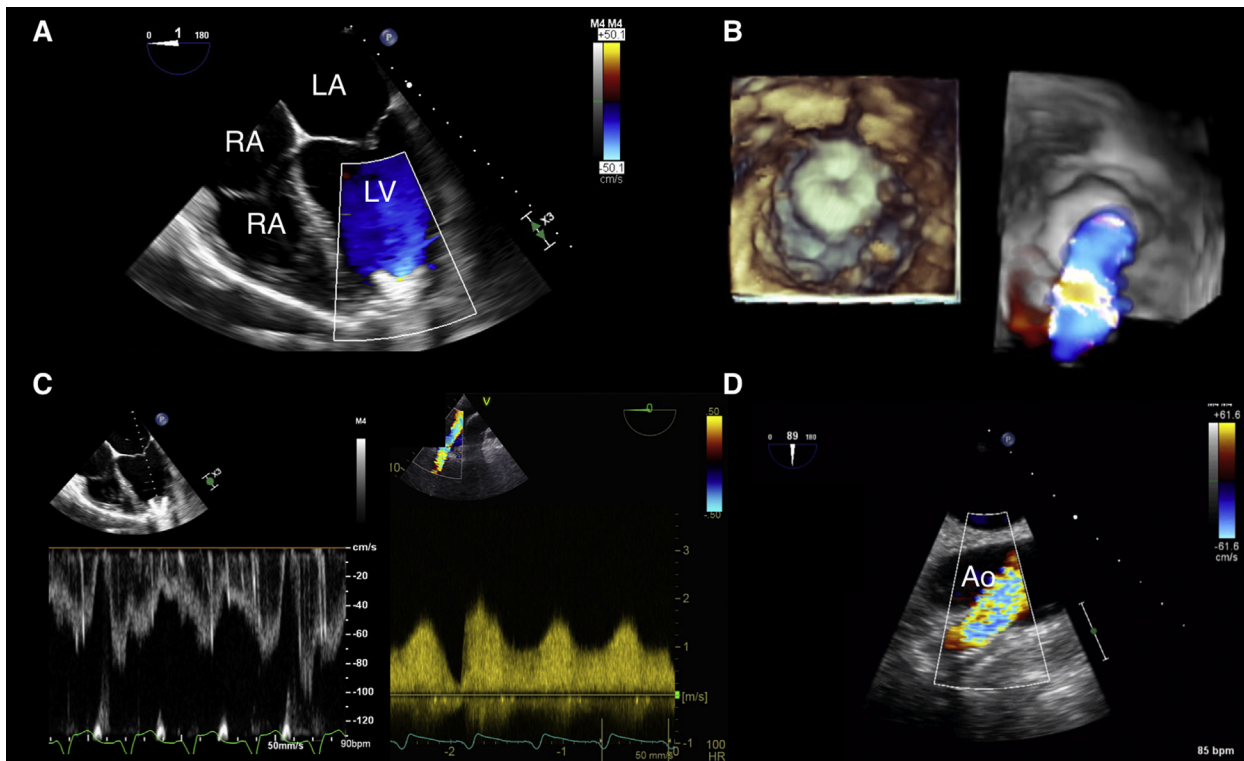


Figure 6 Unobstructed LVAD inflow cannula shown in the ME 4-chamber view (**A**) and by 3D in en face perspective (**B**). (**C**) Doppler interrogation of a HeartMate 3 (Abbott-Thoratec, Chicago, IL) LVAD inflow cannula (left side) and outflow graft (right side). (**D**) CFD interrogation of an LVAD outflow graft-to-ascending aorta anastomosis. Abbreviations: Ao, Ascending aorta; LA, left atrium; LV, left ventricle; RA, right atrium; RV, right ventricle.

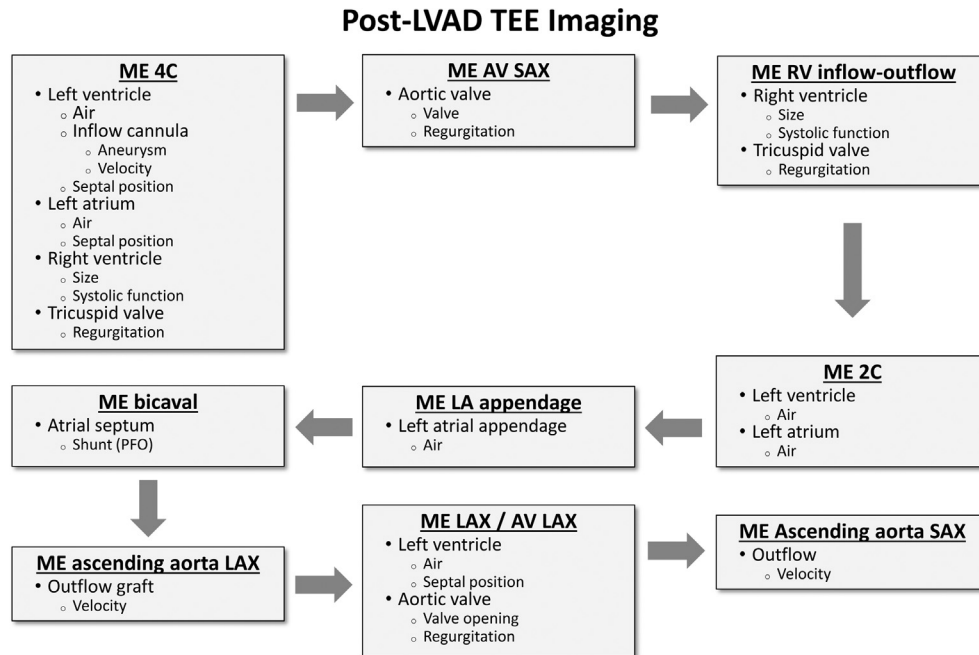


Figure 7 Proposed imaging strategy starting from the ME 4-chamber view for assessment post-left ventricular assist device (LVAD) implantation. Abbreviations: 2C, Two-chamber; 4C, four-chamber; AV, aortic valve; LA, left atrium; LAX, long-axis; ME, mid-esophageal; PFO, patent foramen ovale; RV, right ventricle; SAX, short-axis; TEE, transesophageal echocardiography.

Table 11 Key points for the pre- and postprocedure assessment for intracorporeal LVAD placement

PREPROCEDURE

A complete pre-implantation examination should be performed in order to rule out hemodynamically significant valvular lesions, intracardiac shunts and thrombus, and evaluate baseline RV function.

Evaluation of TR should include assessment of the tricuspid annulus, tricuspid leaflet tethering, RA and RV size, and position and motion of IAS and IVS during the cardiac cycle.

Aortic regurgitation is likely to progress after LVAD implantation and to impair adequate systemic forward flow. It can be easily underestimated in patients with advanced heart failure. Re-evaluation of AR should be performed after institution of CPB, which may mimic the hemodynamic conditions during LVAD support.

RV function should be evaluated by integrating several echocardiographic parameters (Table 1).

POSTPROCEDURE

The same elements of the pre-implantation examination should be re-evaluated in the post-implantation period: intracardiac shunts, degree of TR, degree of AR, and RV function.

The position of the IAS and IVS and the relative size of the LV and RV provide information regarding causes of decreased LVAD flow.

Leftward shift of the IAS and IVS, decreased LV size, RV dilation and dysfunction indicate decreased preload to the LVAD due to RV failure.

Decreased LV and RV size indicate decreased LVAD preload in the setting of hypovolemia or extrinsic compression.

Position and flow by CFD and spectral Doppler should be evaluated and documented for both the inflow cannula and the outflow graft as outlined in the text.

Abbreviations: AR, Aortic regurgitation; CFD, color flow Doppler; CPB, cardiopulmonary bypass; IAS, interatrial septum; IVS, interventricular septum; LVAD, left ventricular assist device; RA, right atrium; RV, right ventricle; TR, tricuspid regurgitation.

origin, multiple jets, a jet path that is visible around the stent or sewing ring, and a visible proximal flow convergence. The ASE guidelines do not recommend the use of jet length or jet area to assess the severity of prosthetic valve regurgitation since these jets are frequently eccentricity-directed, constrained by the LVOT, or entrained within the LVOT, leading to rapid jet broadening.²⁶ Caveats to using quantitative criteria include ventricular

loading conditions and function, as well as ventricular and aortic compliance.

The same Doppler principles and formulas that are used to evaluate native valve stenosis are also applied to prosthetic valvular stenosis.²⁶ Values of quantitative indices that may indicate significant valve obstruction include a peak aortic prosthesis velocity >3 m/s in the presence of an elevated acceleration time (>100 ms) and a low

Table 12 Key points for imaging in percutaneous axial left ventricular assist device placement

Imaging goals	Imaging views	Imaging modalities
BEFORE PLACEMENT		
Exclude contraindications: Severe AS or AR Prosthetic AV LV thrombus Aortic dissection Severe atheromatous disease (mobile components)	ME: 4/5Ch, AV SAX/LAX, ascending aorta SAX/LAX TG: deep 5Ch, LAX Descending aorta: SAX/LAX	<ul style="list-style-type: none"> • 2D, bi/multiplane imaging • CFD • Spectral Doppler • 3D
Other pathologies (relative contraindications): Myxomatous MV Asymmetric septal hypertrophy	ME: 4/5Ch, MC, LAX	<ul style="list-style-type: none"> • 2D, bi/multiplane imaging • CFD • Spectral Doppler • 3D
PLACEMENT AND MONITORING		
Visualize guidewire Adequate position: Inflow 3.5–4 cm from AV Outflow/impeller above the aortic valve; Orientation of the catheter: away from MV, toward LV apex	ME: 4/5 Ch, AV SAX/LAX (inflow depth, AR, outflow/impeller) ME: ascending aorta SAX/LAX (guide wire, outflow/impeller) TG: deep 5Ch, LAX (device depth, AR) Descending aorta: SAX/LAX (guidewire)	<ul style="list-style-type: none"> • 2D: inflow depth from AV, orientation of the catheter, MV morphology • CFD: mosaic pattern of the outflow/impeller in the ascending aorta
LV size		
AR (new or worsened)		
AFTER DEVICE REMOVAL		
Exclude iatrogenic injury AV or MV New/worsened AR New/worsened MR	ME AV SAX, LAX ME 4/5 Ch, MC, 2 Ch, LAX	<ul style="list-style-type: none"> • 2D • CFD

Abbreviations: 2Ch, Two-chamber; 4Ch, four-chamber; 5Ch, five-chamber; 2D, two-dimensional; 3D, three-dimensional; AR, aortic regurgitation; AS, aortic stenosis; AV, aortic valve; CFD, color flow Doppler; LAX, long axis; LV, left ventricle; ME, mid-esophageal; MC, mitral commissural; MR, mitral regurgitation; MV, mitral valve; SAX, short axis; TG, transgastric.

Doppler velocity index (DVI) (<0.27; normal ≥ 0.35).²⁶ As patient-prosthesis mismatch can lead to diminished LV mass regression and poor long-term outcome after AV replacement, the effective orifice area (EOA) of the newly implanted prosthetic valve should be calculated using the continuity equation. The EOA should be compared with other Doppler parameters for concordance and reasons for discordance should be determined.

Key points for postprocedure assessment for AV surgery are presented in Table 5.

3.3. Tricuspid Valve

3.3.1. Preprocedure Assessment. The TV apparatus should be evaluated in the ME and TG views as described in published guidelines.⁸ Primary TV disease is relatively infrequent, therefore comprehensive assessment of left-sided cardiac structures and the pulmonary artery should always be performed in order to rule out causes of secondary or functional TR. The examination should focus on valve anatomy and function, as well as physiologic effects on surrounding structures, such as the RA, RV, and interatrial and interventricular septae. The complex nature of the TV anatomy and the variability in the circumferential and radial size of the TV leaflets may require subtle probe manipulations and non-standard views with biplane imaging for more accurate identification of the TV leaflets.⁸ Surrounding anatomic landmarks can be

used for leaflet identification. The septal leaflet is always adjacent to the IVS, the coronary sinus opens in the RA close to the commissure of the posterior and septal leaflets, and the anterior leaflet is adjacent to the RA appendage as well as the right coronary cusp of the AV.⁵² Surgical patients often have catheters and devices in the RA that may have thrombus or vegetations attached and may contribute to TV leaflet malcoaptation. Individual TV leaflets can be frequently imaged in the TG RV basal view and further identified with simultaneous biplane imaging. 3D imaging enhances identification of the leaflets by examining the TV in an en face fashion either from the RA or from the RV perspective. Imaging of the TV by 3D echocardiography can be challenging as well, because of their thin structure and positioning of the TV in the far field in relation to the probe.

3.3.2. Evaluation of Specific TV Pathologies. Tricuspid Stenosis.—Decreased range of motion of abnormally thickened TV leaflets along with diastolic flow acceleration are the main findings in tricuspid stenosis (TS). The trans-tricuspid diastolic inflow velocity is increased, and the RA is frequently dilated with displacement of the IAS toward the LA. The inferior vena cava and RA appendage may also be dilated, often with spontaneous echogenic contrast. In the hepatic vein velocity profile, a blunted systolic (S) wave suggests elevated RA pressure. The severity of TS should be evaluated per ASE guidelines.¹²

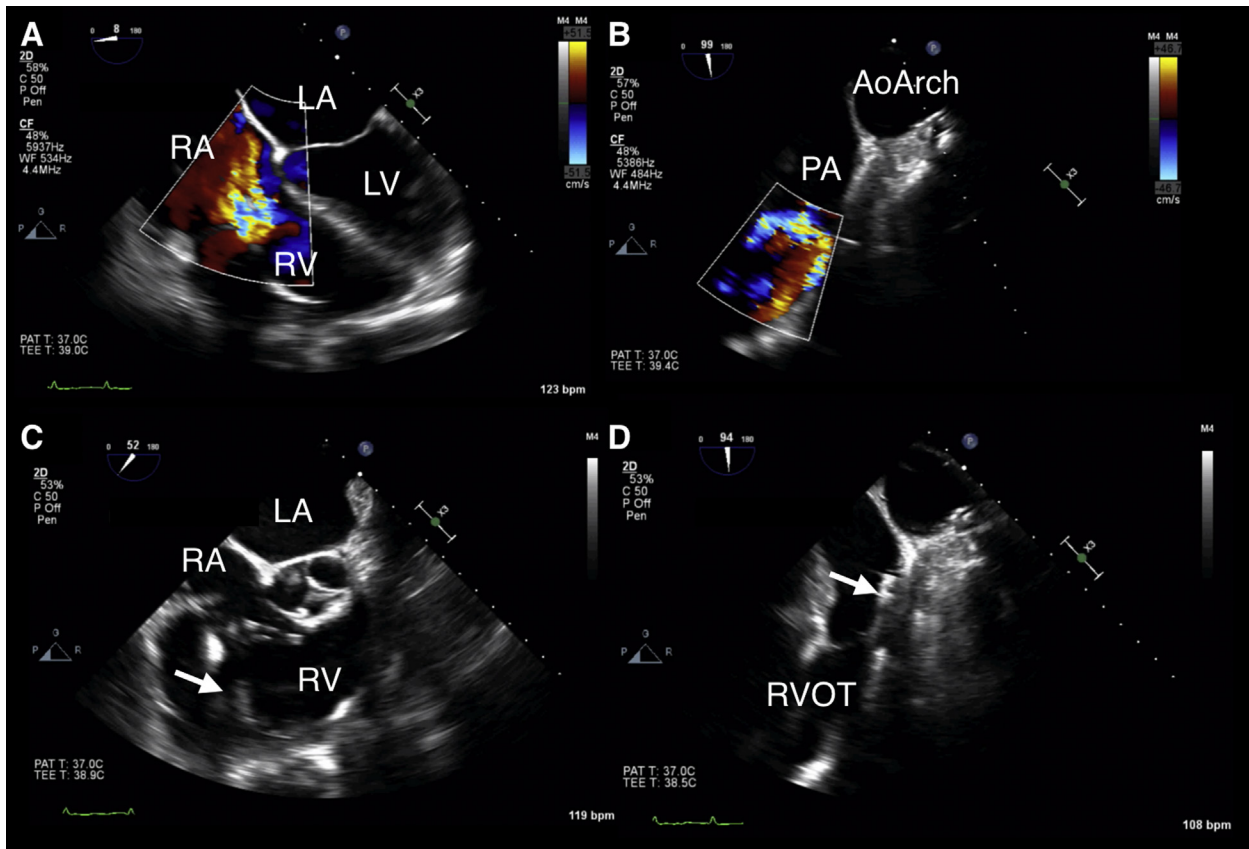


Figure 8 (A) ME 4-chamber view with CFD in a patient with a percutaneous RVAD showing right ventricular (RV) dilation and severe tricuspid regurgitation in the setting of recirculation due to the RVAD outflow cannula situated below the pulmonic valve. (B) Recirculation of flow below the pulmonic valve can be seen with CFD in the UE aortic arch (AoArch) SAX view. (C) ME right ventricle inflow-outflow view showing the percutaneous RVAD (*white arrow*) crossing the tricuspid valve. (D) The RVAD has been advanced, the UE aortic arch SAX view now shows the RVAD outflow (*white arrow*) in adequate position beyond the pulmonic valve, in the main pulmonary artery (PA). Abbreviations: LA, Left atrium; LV, left ventricle; RA, right atrium; RVOT, right ventricular outflow tract.

Tricuspid Regurgitation.—Echocardiographic assessment of TR should be performed by employing several imaging modalities: 2D and 3D echocardiography, with color flow, continuous-wave (CW), and PW Doppler, according to the published ASE guidelines.² An important aspect of evaluation of TR is the assessment of tricuspid annular (TA) dilation and RV remodeling. Based on the current evidence, significant annular dilation is defined as an end-diastolic diameter of >40 mm (>21 mm/m²) and is part of the decision algorithm for TV surgery in functional TR.³⁴ More recently, investigators have used the TA measurement in the ME 4Ch view as a measurement of the septal-lateral diameter of the TA along the anterolateral-posteroseptal axis of dilation.⁵³ Measurement of the TA can also be performed by 3D multiplanar reconstruction. RV remodeling can result in changes in the geometry of the TV. Leaflet tethering greater than 0.76 cm and a tethering area greater than 1.63 cm² have been associated with residual TR after TV annuloplasty.⁵⁴

3.3.3. Postprocedure Assessment. Postprocedure intraoperative evaluation of the repaired/replaced TV requires assessment for iatrogenic tricuspid stenosis and residual tricuspid regurgitation and relies on the same imaging modalities used for the native valve; CFD is used for detection of residual TR, and measurement of diastolic transvalvular pressure gradients by spectral Doppler is performed to exclude iatrogenic TS.

Key points for the pre- and postprocedure assessment in patients undergoing TV surgery are presented in [Table 6](#).

3.4. Pulmonary Valve

3.4.1. Preprocedure Assessment. The pulmonary root consists of the right ventricular outflow tract (RVOT), the pulmonary valve, the interleaflet triangles, and the pulmonary sinuses of Valsalva. Significant pulmonary valve pathology can be present in carcinoid syndrome, endocarditis, and congenital diseases such as repaired tetralogy of Fallot or congenital pulmonary valve stenosis. The assessment should include leaflet morphology and motion, annular size, valve/leaflet symmetry, and leaflet integrity. The dimensions, sizes, and function of a normal, native pulmonary valve are particularly important when a Ross procedure or a transcatheter pulmonary valve replacement for a diseased native or prosthetic heart valve is planned. The pulmonary valve can be imaged at the upper esophageal (UE), ME, and TG views as recommended in published ASE guidelines.⁸

3.4.2. Evaluation of Specific PV Pathologies. Pulmonic Stenosis.—In adults, pulmonic stenosis (PS) occurs most often due to

Table 13 Key points for imaging in patients undergoing right ventricular assist device placement

Imaging goals	Imaging views	Imaging modalities
BEFORE PLACEMENT		
Evaluate inflow site: RA: exclude masses, Chiari network, IAS aneurysm IVC: exclude thrombus SVC: exclude thrombus	ME: 4/5 Ch, modified ME bicaval, RV inflow/outflow	<ul style="list-style-type: none"> • 2D, bi/multiplane imaging • CFD • 3D
Evaluate outflow site Main PA: exclude masses	ME ascending aorta SAX UE aortic arch SAX	<ul style="list-style-type: none"> • 2D, bi/multiplane imaging • CFD • 3D
Exclude intracardiac shunts: PFO ASD	ME: 4/5 Ch, bicaval, RV inflow/outflow	<ul style="list-style-type: none"> • 2D, bi/multiplane imaging • CFD • Spectral Doppler
Evaluate valve function: Presence/severity TR Presence/severity PR Prosthetic TV, PV (preclude placement of percutaneous devices)	ME: 4/5 Ch, RV inflow/outflow, bicaval, ascending aorta SAX TG: basal RV, RV inflow/outflow, RV inflow UE: aortic arch SAX	<ul style="list-style-type: none"> • 2D, bi/multiplane imaging • CFD • Spectral Doppler
AFTER PLACEMENT		
Evaluate inflow: At IVC-RA junction or SVC-RA junction for percutaneous devices	ME: 4/5 Ch, bicaval, RV inflow/outflow UE: aortic arch SAX	<ul style="list-style-type: none"> • 2D • CFD • 3D
Evaluate outflow: Beyond the PV; In the main PA (not preferentially to the left/right PA)		
Evaluate RV size/function Appropriate decompression	ME: 4/5 Ch, RV inflow/outflow, bicaval, ascending aorta SAX	<ul style="list-style-type: none"> • 2D • CFD
Evaluate new/worsened TR May be due to RV dilation	TG: basal RV, RV inflow/outflow, RV inflow UE: aortic arch SAX	<ul style="list-style-type: none"> • 3D • Spectral Doppler
Evaluate new/worsened PR May lead to RV dilation in spite of normal device flows		

Abbreviations: *2Ch*, Two-chamber; *4Ch*, four-chamber; *5Ch*, five-chamber; *2D*, two-dimensional; *3D*, three-dimensional; *ASD*, atrial septal defect; *CFD*, color flow Doppler; *IAS*, interatrial septum; *IVC*, inferior vena cava; *IVS*, interventricular septum; *LAX*, long axis; *ME*, mid-esophageal; *PA*, pulmonary artery; *PFO*, patent foramen ovale; *PV*, pulmonic valve; *PR*, pulmonic valve regurgitation; *RA*, right atrium; *RV*, right ventricle; *SAX*, short axis; *SVC*, superior vena cava; *TG*, transgastric; *TR*, tricuspid regurgitation; *TS*, tricuspid stenosis; *TV*, tricuspid valve.

congenital disease (residual stenosis after prior repair, congenitally corrected transposition of the great arteries, tetralogy of Fallot), but can also develop as a result of carcinoid disease. In patients with carcinoid syndrome, the pulmonary valve leaflets appear thickened, with calcification and systolic “doming”.

Measurement of pressure gradients is the mainstay of evaluation of PS.¹² It should be differentiated from sub- or supra-valvular stenosis, and the main pulmonary artery (PA) should be imaged for the presence of post-stenotic dilatation. RVOT obstruction can occur from hypertrophy of the infundibular septum, aneurysm of the membranous ventricular septum, cardiac tumors, and compression by a dilated right aortic sinus of Valsalva.

Pulmonic Regurgitation.—Pulmonic regurgitation (PR) is usually well tolerated unless it is severe. Severe PR is usually congenital, or a sequela of prior corrective surgery (e.g., following correction of tetralogy of Fallot, or patch augmentation of congenital pulmonary valve stenosis). It can also be the result of pulmonary hypertension (leading to pulmonic annular dilatation), carcinoid syndrome (thickened leaflets, and with restricted motion in systole and diastole), endocarditis, myxomatous degeneration (rare),

Marfan syndrome, or following balloon dilation of congenital pulmonary valve stenosis. Prior ventricular septal defect (VSD) repair may result in distortion of the pulmonary valve anatomy, leading to PR. Criteria for grading the severity of PR have been described in the relevant ASE guidelines.²

3.4.3. Postprocedure Assessment. Postprocedure intraoperative evaluation of the replaced pulmonary valve requires assessment for PS and residual PR and relies on the same imaging modalities used for the native valve; CFD is used for detection of residual PR and spectral Doppler is used to measure systolic transvalvular pressure gradients in order to exclude iatrogenic PS.

Impingement or distortion of coronary arteries has been described after both surgical and transcatheter pulmonary valve replacement; therefore, a complete examination of LV and RV wall motion should be performed to exclude this complication.^{55,56}

Key points for pre- and postprocedure assessment in patients undergoing pulmonary valve surgery are presented in [Table 7](#).

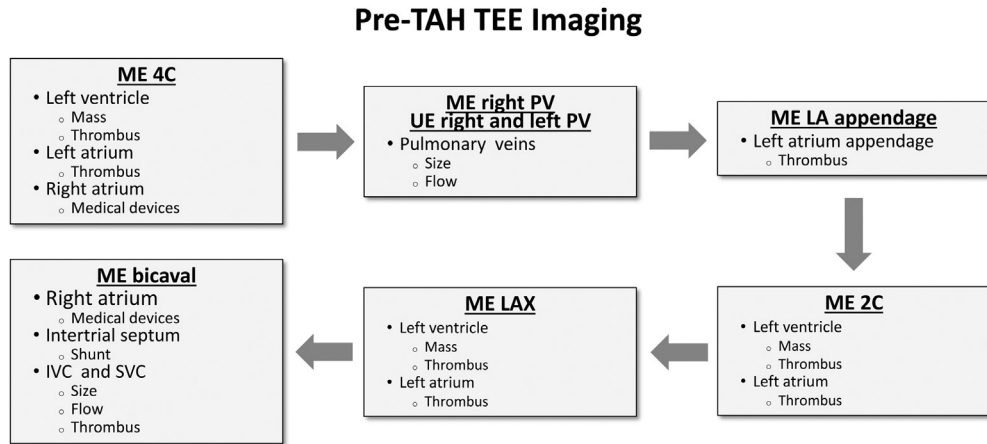


Figure 9 Proposed imaging strategy starting from the ME 4-chamber view for assessment prior to implantation of a total artificial heart (TAH). Abbreviations: 2C, Two-chamber; 4C, four-chamber; AV, aortic valve; IVC, inferior vena cava; LA, left atrium; ME, mid-esophageal; PV, patent foramen ovale; PV, pulmonary vein; RA, right atrium; TEE, transesophageal echocardiography.

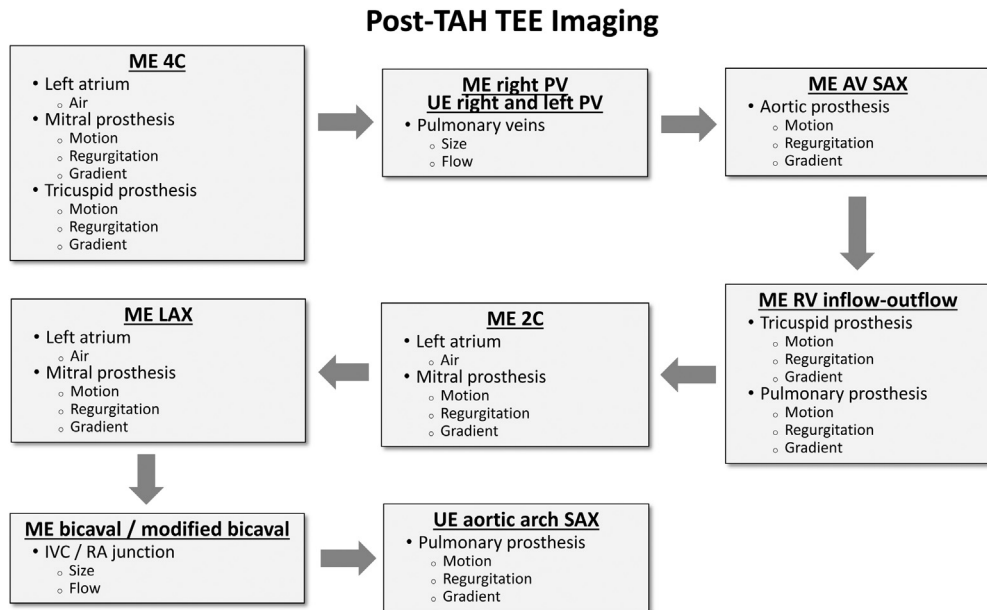


Figure 10 Proposed imaging strategy starting from a ME 4-chamber view for assessment after implantation of a total artificial heart (TAH). Abbreviations: 2C, Two-chamber; 4C, four-chamber; AV, aortic valve; IVC, inferior vena cava; LA, left atrium; ME, mid-esophageal; PFO, patent foramen ovale; PV, pulmonary vein; RA, right atrium; RV, right ventricle; SAX, short-axis; TEE, transesophageal echocardiography; UE, upper esophageal.

4. CORONARY ARTERY DISEASE

The utility of TEE in coronary artery bypass graft (CABG) surgery has been supported by previous guidelines.^{1,7} Given the dynamic aspect of coronary artery disease (CAD), the role of TEE in these procedures is complementary to the preoperative work-up of the patient for confirming the diagnosis, excluding new valvular dysfunction, and diagnosing unrecognized abnormalities.

4.1. Preprocedure Assessment

The heterogeneous nature of CAD mandates a comprehensive TEE examination, as detailed in the ASE practice guidelines.⁸ For the pa-

tient undergoing CABG surgery, the focus is evaluation of systolic function of both ventricles, grading of the severity of diastolic dysfunction, estimation of volume dependency and filling pressures, assessment of any valvular dysfunction, and examination of the aorta for atheromatous disease. Specific attention also should be given to the diagnosis of possible mechanical complication of myocardial infarction, such as ruptured papillary muscle or infarct-related ventricular septal defect.

Evaluation of ventricular dysfunction is particularly important in defining a plan for management of the patient at separation from CPB or in the post-CPB period, as inotropic or temporary mechanical circulatory support may be needed in high-risk patients after surgical revascularization. LV shape and size, wall thickness, and the presence

Table 14 Key points for imaging in patients undergoing total artificial heart placement

PREPROCEDURE

Examine left and right atria as well as the LAA and exclude the presence of thrombus.

Examine left and right pulmonary veins and document size and pulmonary vein flow (flow profile and velocities by PW Doppler).

Inspect RA-SVC and RA-IVC junctions for the presence of medical devices, thrombus, stenosis.

POSTPROCEDURE

Monitor for the presence of air in the native atria, and in the main PA and ascending aorta.

Re-evaluate size of the atria and pulmonary vein flow (flow profile and velocities) to rule out torsion or extrinsic compression.

Obstruction of PV flow should be suspected if there is loss of phasic systolic and diastolic flow patterns, CFD flow acceleration is detected, and peak velocities are increased above normal or baseline values.

Mean gradients and the corresponding ventricular rate should be recorded for the tricuspid and mitral prostheses in order to serve as a reference for subsequent examinations.

Abbreviations: *CFD*, Color flow Doppler; *IVC*, inferior vena cava; *LAA*, left atrial appendage; *PA*, pulmonary artery; *PV*, pulmonary vein; *RA*, right atrium.

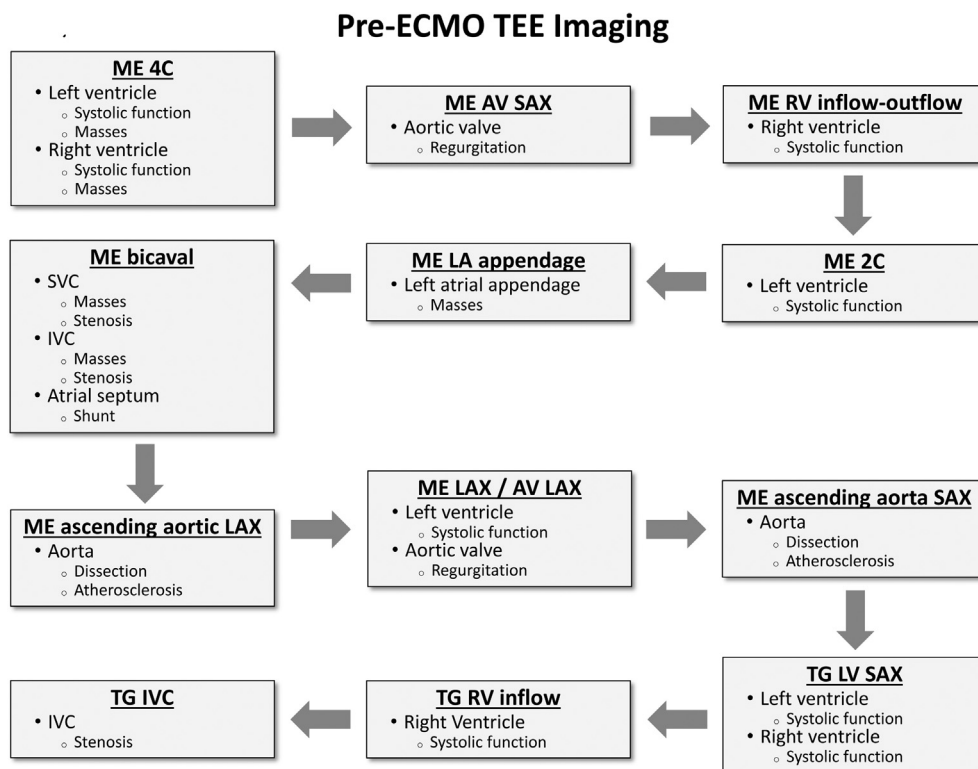


Figure 11 Proposed imaging strategy starting from a ME 4-chamber view for assessment before deployment of extracorporeal membrane oxygenation (ECMO). Abbreviations: 2C, Two-chamber; 4C, four-chamber; AV, aortic valve; IVC, inferior vena cava; LA, left atrium; LV, left ventricle; ME, mid-esophageal; RV, right ventricle; SAX, short-axis; SVC, superior vena cava; TEE, transesophageal echocardiography; TG, transgastric.

of aneurysms or low-flow state (spontaneous echo contrast) should be evaluated in ME and TG views. Qualitative and quantitative assessment of systolic function should be performed by 2D and 3D echocardiographic methods as recommended by the ASE guidelines for chamber quantification.⁹ Simultaneous orthogonal imaging can be used in the ME views to avoid LV foreshortening. Wall motion abnormalities should be noted at baseline and compared with the post-revascularization examination. RV size and function should be evaluated (Table 2) in multiple tomographic views as well.

Evaluation of diastolic function is useful for hemodynamic management. The presence of an impaired relaxation pattern will indicate dependency on preload and atrial contraction, whereas a restrictive pattern may suggest dependency on heart rate in order to maintain an adequate cardiac output in the presence of fixed stroke volume.^{57,58}

Valvular dysfunction should be noted, as any unrecognized, significant lesions may result in alteration of the surgical plan (e.g., MV repair or replacement for moderate or severe MR, or AV replacement for severe AS) or in a change in the perfusion strategy (e.g., retrograde

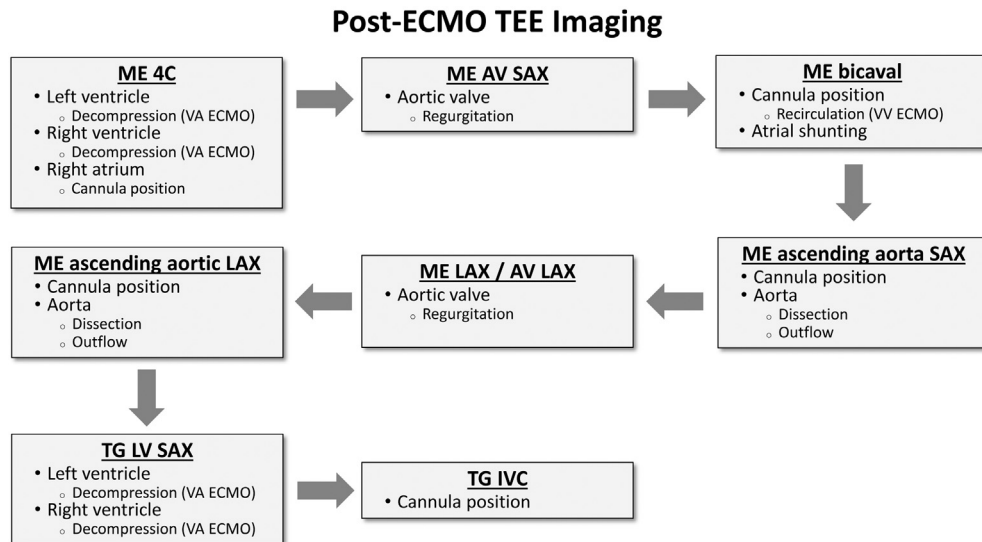


Figure 12 Proposed imaging strategy starting from a ME 4-chamber view for assessment after deployment of extracorporeal membrane oxygenation (ECMO). Abbreviations: 2C, Two-chamber; 4C, four-chamber; AV, aortic valve; LV, left ventricle; ME, mid-esophageal; SAX, short-axis; TEE, transesophageal echocardiography; TG, transgastric; VA, veno-arterial; VV, veno-venous.

cardioplegia, or placement of a left ventricular vent if significant AR is present).

Finally, preprocedure imaging should include the evaluation of the descending aorta, aortic arch, and proximal ascending aorta for the presence of atheromas. Significant atheromatous disease may influence the position of the aortic cannulation site, placement of aortic cross-clamp, or placement of an intra-aortic balloon pump (IABP) for hemodynamic support. As the aortic cannulation site cannot be visualized by TEE, epiaortic imaging may be utilized by the surgeon if significant atheromatous burden is noted in other aortic locations.⁵⁹

4.2. Postprocedure Assessment

TEE is instrumental in refining preload, afterload, and inotropic support at separation from CPB by providing anatomic and functional information regarding LV and RV filling and function.

A comprehensive TEE examination should also be performed after the procedure. Specific issues that should be addressed are: (1) assessment of regional and global myocardial function, specifically in the segments perfused by the bypassed coronary vessels; this examination should be performed periodically during the post-CPB period as kinking of the graft can occur at any time, but especially after reapproximation of the sternum; (2) detection of significant complications related to cannulation (e.g., aortic dissection in the ascending aorta), entrainment of air, or myocardial protection; and (3) assessment of valvular function.

Key points in the pre- and postprocedure assessment for CABG surgery are presented in [Table 8](#).

5. AORTIC SURGERY

5.1. Preprocedure Assessment

The ASE/SCA guidelines for comprehensive TEE imaging recommend a systematic approach for imaging the thoracic aorta from the aortic root to the descending aorta.⁸ Using simultaneous multi-

plane imaging ensures that the aortic root and proximal ascending aorta are imaged at the desired level and that the largest dimension is measured perpendicular to the long axis of the vessel.

By convention, measurements of the aortic root, i.e., sinuses of Valsalva, sinotubular junction, and tubular portion of the ascending aorta, are made in *diastole*, leading edge to leading edge⁹; note, however, that echocardiographic laboratories frequently perform these measurements during systole. Off-line, multiplanar reconstruction of 3D volume data sets may enable these measurements.

Abnormalities within the descending thoracic aorta can be localized by describing the location of the defect as a distance from the origin of the left subclavian artery, its location on the vessel wall relative to the position of the esophagus (e.g., the wall opposite the esophagus), or depth of the probe from the incisors.

5.2. Evaluation of Specific Aortic Pathologies

Atheroma Assessment.—TEE is recommended as the first-line choice of imaging modality for the diagnosis of aortic atherosclerosis by the 2015 ASE guidelines document on multimodality imaging of diseases of the thoracic aorta.⁶⁰ Based on the review of several classification schemes, the ASE guidelines recommend grading aortic atherosclerotic disease according to increasing thickness of the lesion: grade 1 (intimal thickness <2 mm), grade 2 (intimal thickening 2-3 mm), grade 3 (atheroma thickness 3-5 mm), grade 4 (atheroma thickness >5 mm), and grade 5 (any atheroma thickness with mobile or ulcerated components).⁶⁰ There are several limitations to TEE evaluation of aortic atherosclerotic disease: presence of near-field artifacts, one-dimensional measurement of a three-dimensional lesion, not accounting for the total plaque area (i.e., “atheroma burden”), and a highly subjective assessment of atheroma characteristics (e.g., density, texture, presence of calcifications).

Aortic Dissection.—TEE is fundamental in confirming the diagnosis of aortic dissection and assessing the complications associated with

Table 15 Key points for imaging in extracorporeal membrane oxygenation deployment, monitoring, and weaning

DEPLOYMENT
Have complete understanding of the intended cannulation strategy
Exclude new reversible pathology (e.g., cardiac tamponade)
VV-ECMO: exclude severe RV dysfunction and tricuspid valve stenosis
VA-ECMO: exclude presence of aortic dissection and severe aortic regurgitation
VA-ECMO: describe presence, distribution, and severity of aortic atherosclerotic disease
VA- and VV-ECMO: evaluate right atrium for the presence of thrombus, masses, intracardiac shunts, pacemaker leads
MONITORING
Evaluate cannula positions (imaging views employed may vary depending on type of ECMO and cannula configurations)
VV-ECMO: ensure that drainage and return cannulas are not in proximity. This will avoid recirculation
VA-ECMO: evaluate degree of LV decompression. Failure to decompress leads to severe MR, and LV stasis and thrombosis
VA-ECMO: evaluate opening of aortic valve. Failure of aortic valve opening leads to stasis and thrombosis on the aortic valve cusps and aortic root
VA- and VV-ECMO: exclude cardiac tamponade
RECOVERY AND WEANING
Continuous echocardiographic monitoring should be performed during decremental decrease in VA- ECMO flow
Parameters suggestive of a higher likelihood of successful VA-ECMO weaning: LV EF 20-25%, LVOT VTI >10 cm, mitral annulus S' >6 cm/sec

Abbreviations: *ECMO*, Extracorporeal membrane oxygenation; *EF*, ejection fraction; *LV*, left ventricle; *S'*, systolic velocity by tissue Doppler imaging; *VA*, veno-arterial; *VV*, veno-venous

Table 16 Key points for imaging during intra-aortic balloon pump placement

PREPROCEDURE
Exclude the presence of moderate or severe aortic regurgitation
Examine the presence of mobile atheromatous disease
POSTPROCEDURE
Note the presence of the tip of the intra-aortic balloon pump 1-2 cm below the distal aortic arch (left subclavian artery)
Balloon inflation during diastole will generate characteristic acoustic shadowing and reverberation artifacts

it, and should be performed in all patients undergoing repair for type A dissection (involvement of ascending aorta present). Intraoperative TEE should be used to identify the presence of the dissection flap, define the extent of the aortic dissection (e.g., proximal to the aortic root and distal to the subdiaphragmatic descending aorta), identify the true and false lumens, and localize the entry tear.⁶⁰ Complications associated with aortic dissection that should be ruled out include involvement of coronary arteries (flow in the coronaries seen by CFD, wall motion abnormalities) and/or major side branches, pericardial effusion and cardiac tamponade, pleural effusion, and aortic regurgitation.

It is important to differentiate a dissection flap from artifacts such as side lobe, mirror image, or reverberations.

Differentiation between true and false lumens is important, particularly if instrumentation of the aorta is planned (e.g., cannulation, placement of guidewires). The larger lumen is typically the false lumen, especially further distal in the aortic arch and descending aorta, in both chronic and acute dissections.⁶¹ The true lumen displays higher blood velocities in systole by PW Doppler. M-mode imaging can help determine the direction of movement of the flap in systole, and thereby identify the true lumen, which shows expansion during systole. The false lumen shows spontaneous echo contrast and has an increased likelihood of thrombosis.⁶²

Intimal tear(s) can be localized in 78-100% of patients. In addition, variants of acute aortic syndromes such as intramural hematoma, atherosclerotic penetrating ulcers, and side branch obstruction can also be identified.⁶²

When significant AR complicates acute type A aortic dissection, TEE is paramount in defining the severity and mechanisms of AR and can assist the surgeon in identifying patients in whom valve repair is likely to be successful, as preservation of the aortic valve can be achieved in up to 86% of ascending aortic dissections.^{63,64} Several mechanisms for AR in type A aortic dissection have been described: (1) incomplete closure of otherwise normal leaflets due to leaflet tethering by a dilated sinotubular junction; (2) leaflet prolapse due to leaflet attachment disruption by a dissection flap extending into the aortic root; and (3) prolapse of the dissection flap that disrupts coaptation of intrinsically normal leaflets.⁶³ Evaluation of AR and suitability for repair is presented in section 3.2.2.

Aortic Aneurysm.—For the patients who present for aortic aneurysm surgery, the anatomy of the aorta has usually been thoroughly investigated preoperatively. Nonetheless, intraoperative TEE is useful in characterization of the aneurysmal involvement of the aortic root, ascending aorta, and aortic valve.

Key points for the preprocedure assessment for aortic surgery are presented in Table 9.

5.3. Postprocedure Assessment

During the procedure, TEE is instrumental in aiding with cannulation and placement of guidewires, for both open and hybrid procedures. Venous drainage cannulas may be placed in the RA through the femoral vein, with TEE confirming the presence of the guidewire, and subsequently the cannula, in the RA using the ME bicaval view.

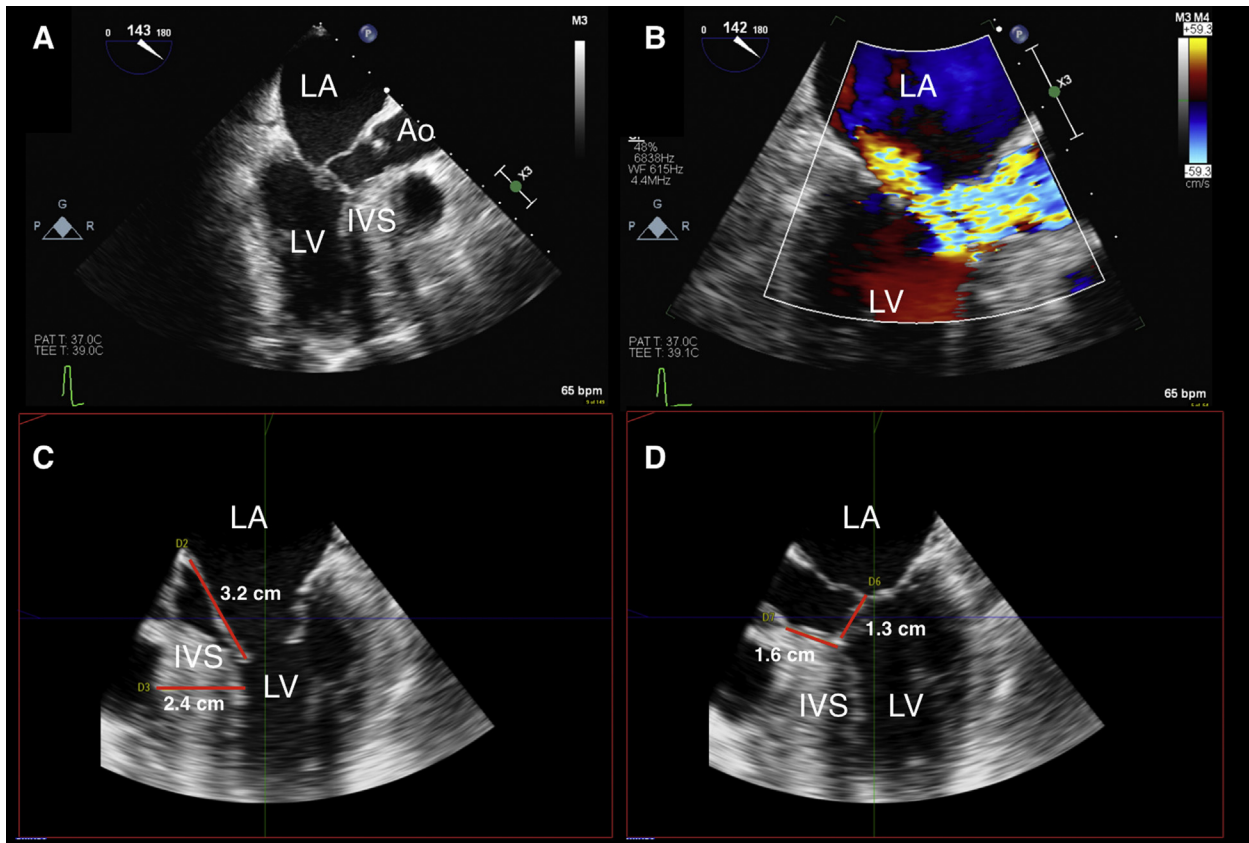


Figure 13 (A) ME LAX view showing systolic anterior motion of the mitral valve, the anterior leaflet (AL) making contact with the inter-ventricular septum (IVS). (B) ME LAX view with color flow Doppler showing posteriorly directed mitral regurgitation, and flow acceleration in the left ventricular (LV) outflow tract, which seems to originate at the level of contact of the mitral valve with the IVS. (C) Measurements of the IVS maximum thickness (2.4 cm) and AL length (3.2 cm) performed using multiplanar reconstruction of a 3D data set. (D) Measurements of the redundant length of the AL beyond coaptation (1.3 cm) and the distance from the aortic annulus to septal contact (1.6 cm) performed using multiplanar reconstruction of a 3D data set. Abbreviations: Ao, Ascending aorta; LA, left atrium; LV, left ventricle.

Guidewires are placed in the true lumen of an aortic dissection either for cannulation purposes or for stent deployment. Special attention should be given to the open repair of a descending thoracic aneurysm performed on partial left heart bypass. In this configuration of partial extracorporeal circulatory support, a drainage cannula is placed in the left upper pulmonary vein and blood is returned to the patient in the descending aorta or femoral artery, distal to the aortic cross-clamp. TEE is a versatile tool for monitoring ventricular filling and contractility in order to ensure adequate drainage for circulatory support distal to the aortic cross-clamp and adequate preload for hemodynamic stability proximal to the aortic cross-clamp.

Immediately after separation from CPB, TEE should be used to systematically evaluate anatomic features of the aorta and aortic valve, with emphasis on certain elements depending on the procedure performed. The aortic valve repair or replacement should be evaluated as described in section 3.2.4. If aortic root replacement has been performed with reimplantation of the coronary arteries, adequate flow should be evaluated with CFD in the implanted coronaries, the motion of wall segments should be inspected, and wall motion abnormalities should be noted and discussed with the surgical team. This assessment should continue in the post-CPB period, as kinking and distortion of coronary arteries could occur at different times during surgical manipulation or sternal closure. Specifically, for aortic dissec-

tion, the aorta should be assessed to ensure that the entry tear and false lumen have been excluded and that flow has been restored to the true lumen.

In hybrid and endovascular procedures, TEE is useful in detecting endoleaks, defined as persistent blood flow outside of the lumen of the endograft and within the aneurysmal sac or an adjacent vascular segment.^{65,66} The echocardiographer should be alerted to the presence of an endoleak by the presence of swirling spontaneous echo contrast, denoting residual flow within the aneurysmal sac. A type I endoleak represents persistent flow around the attachment sites (proximal or distal), type II occurs due to retrograde flow from a patent collateral branch vessel into the aneurysmal sac, type III represents flow into the aneurysmal sac through a tear, defect, or between the modular segments of an endograft, and type IV represents flow through the porosity of the stent.⁶⁶

One of the most important roles of TEE in endovascular procedures is the recognition of retrograde iatrogenic aortic dissection. Iatrogenic aortic dissection is rare, with a reported incidence of 1.9%, but is associated with a high mortality (33%).⁶⁷ Careful survey of the ascending aorta and aortic arch should be performed in order to document integrity.

Key points for the assessment of the aorta after aortic surgery are presented in Table 10.

Table 17 Key points for imaging in patients with hypertrophic cardiomyopathy undergoing septal reduction surgery

Imaging goals	Imaging views	Imaging modalities	Limitations
Evaluate LVOT gradient Presence of flow acceleration (LVOT, mid-cavitary) Peak velocity Peak pressure gradient “Dagger-shaped” Doppler envelope	ME: 4/5 Ch, LAX TG: deep 5Ch, LAX	<ul style="list-style-type: none"> • 2D, bi/multiplane imaging • CFD • Spectral Doppler 	<ul style="list-style-type: none"> • Contamination from co-existing MR • Doppler misalignment • Loading conditions
Evaluate LV IVS thickness and extension Note other LV abnormalities: abnormal number/insertion papillary muscles Distribution of hypertrophy	ME: 4/5Ch, 2Ch LAX TG: basal SAX, mid SAX, 2Ch	<ul style="list-style-type: none"> • 2D, bi/multiplane imaging • 3D 	<ul style="list-style-type: none"> • 2D: off-axis measurements • 3D: lower spatial resolution
Evaluate mitral valve Presence of SAM Anterior leaflet length Redundant anterior leaflet extending past coaptation point Exclude other pathology (e.g., clefts, prolapse)	ME: 4/5Ch, LAX TG: basal SAX, 2Ch (subvalvular apparatus)	<ul style="list-style-type: none"> • 2D, bi/multiplane imaging • CFD • M-mode • 3D 	<ul style="list-style-type: none"> • 2D: off-axis measurements • Loading conditions may affect SAM
Evaluate MR Posteriorly oriented, dynamic If MR central/anterior jet, then it is independent of SAM Grade MR severity	ME: 4/5Ch, MC, 2Ch LAX	<ul style="list-style-type: none"> • 2D • CFD • Spectral Doppler • 3D with CFD 	<ul style="list-style-type: none"> • Loading conditions affect MR appearance and severity
Evaluate AV Concomitant AS Presence/severity of AR Premature systolic closure due to LVOT obstruction; Subaortic membrane	ME: AV SAX/LAX TG: deep 5Ch, LAX	<ul style="list-style-type: none"> • 2D, bi/multiplane imaging • M-mode (premature AV systolic closure) • 3D • CFD • Spectral Doppler 	<ul style="list-style-type: none"> • If significant AS present, difficult to differentiate LVOT gradient from AV gradient • Concomitant AR may increase flow across the LVOT/AV

Abbreviations: 2Ch, Two-chamber; 4Ch, four-chamber; 5Ch, five-chamber; 2D, two-dimensional; 3D, three-dimensional; AR, aortic regurgitation; AV, aortic valve; AS, aortic stenosis; CFD, color flow Doppler; LAX, long axis; LV, left ventricle; LVOT, left ventricular outflow tract; ME, mid-esophageal; MR, mitral regurgitation; SAM, systolic anterior motion; SAX, short axis; TG, transgastric.

6. MECHANICAL CIRCULATORY SUPPORT

Advancements in the technology of ventricular assist devices (VAD) have led to improvement in their efficacy, ease of implantation, duration of support, and patient outcomes, which will likely continue to drive an increasing number of implantations in a fast-growing population of heart failure patients.^{68,69} The section below focuses on the perioperative use of TEE for patients undergoing placement of durable or temporary mechanical circulatory support (MCS).

6.1. Left Ventricular Assist Device

Intracorporeal left ventricular assist devices (LVAD) are intended to serve as a bridge to transplantation or recovery, or as destination therapy. These devices are typically configured for axial or centrifugal flow with the inflow conduit positioned in the LV apex, and the outflow graft anastomosed to the ascending aorta, or rarely, to the descending aorta in patients with significant ascending aortic pathology. An impeller, interposed between device inflow and outflow, resides

either above the diaphragm (HeartWare HVAD, HeartWare International, Framingham, MA and HeartMate 3, Abbott-Thoratec, Chicago, IL) or below the diaphragm (HeartMate II, Abbott-Thoratec, Chicago, IL).

Recent guidelines emphasize the key role of echocardiography in the perioperative care of LVAD patients.^{70,71} Although the vast majority of patients presenting for LVAD implantation undergo preoperative TTE studies, a comprehensive intraoperative TEE examination should be performed prior to device placement. Improved visualization of a number of cardiac structures with TEE affords the opportunity to detect important conditions that may have escaped detection during surface echocardiograms, such as the presence of interatrial shunts, intracardiac masses, or aortic regurgitation, which may require surgical attention at the time of LVAD placement and may alter the surgical plan.

6.1.1. Preprocedure Assessment. The pre-implantation echocardiographic focus is on LVAD cannulation sites (LV apex and aorta), exclusion of hemodynamically significant valve lesions, detection of LAA or LV masses or thrombus, and evaluation of baseline RV function, using recommended views and guidelines.

Table 18 Key points for imaging postprocedure in patients with hypertrophic cardiomyopathy undergoing septal reduction surgery

Imaging goals	Imaging views	Imaging modalities	Limitations
Optimize loading conditions (preload, afterload) and heart rate			
Evaluate LVOT obstruction Presence of flow acceleration; LVOT gradient (at rest and with dobutamine infusion 10 μ g/kg/min and appropriate heart rate increase)	ME: 4/5Ch, LAX TG: deep 5Ch, LAX	<ul style="list-style-type: none"> • 2D • CFD • Spectral Doppler • 3D 	<ul style="list-style-type: none"> • “Contamination” by co-existing MR • Doppler misalignment • Loading conditions
Evaluate MV and residual MR Integrity of MV Residual MR Differentiate from (new) anterior MR jet (uncovered organic MV disease); Ensure absence of iatrogenic MS	ME: 4/5Ch, MC, 2Ch, LAX TG: basal SAX, 2Ch	<ul style="list-style-type: none"> • 2D • CFD • Spectral Doppler • 3D 	<ul style="list-style-type: none"> • Loading conditions
Evaluate IVS Rule out iatrogenic VSD in multiple views; Measure residual IVS thickness	ME: 4/5 Ch, LAX TG: basal SAX, mid SAX, deep 5Ch, LAX	<ul style="list-style-type: none"> • 2D • CFD • 3D • Spectral Doppler: Qp/Qs 	<ul style="list-style-type: none"> • Differentiate from septal perforators • Artifacts (shadowing, reverberations)
Evaluate AV New/worsened AR	ME: AVSAX/LAX TG: deep 5Ch, LAX	<ul style="list-style-type: none"> • 2D • CFD • 3D 	<ul style="list-style-type: none"> • Differentiate from septal perforators

Abbreviations: 2Ch, Two-chamber; 4Ch, four-chamber; 5Ch, five-chamber; 2D, two-dimensional; 3D, three-dimensional; AR, aortic regurgitation; AV, aortic valve; CFD, color flow Doppler; IVS, interventricular septum; LAX, long axis; LVOT, left ventricular outflow tract; ME, mid-esophageal; MR, mitral regurgitation; MS, mitral stenosis; MV, mitral valve; Qp/Qs, pulmonary to systemic flow ratio; SAX, short axis; TG, transgastric; VSD, ventricular septal defect.

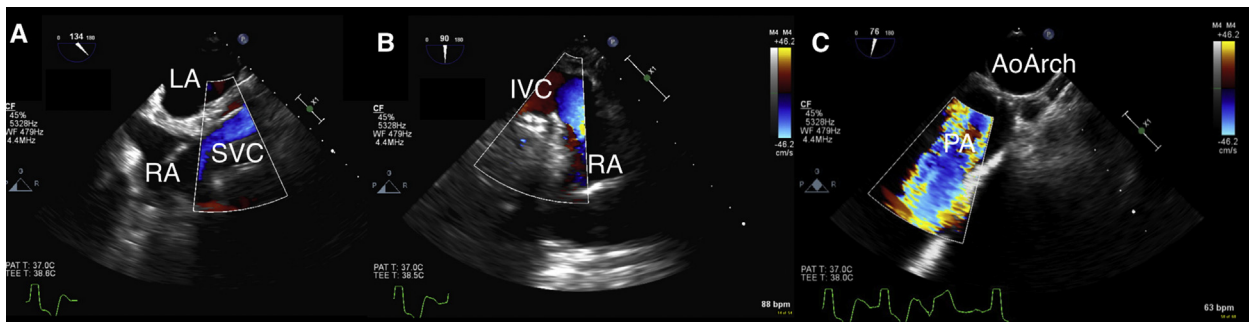


Figure 14 (A) ME bicaval view showing laminar flow by CFD of the superior vena cava (SVC)-right atrium (RA) anastomosis after heart transplantation. (B) Non-standard view of the inferior vena cava (IVC)- RA anastomosis showing laminar flow by CFD. (C) CFD interrogation of an unobstructed pulmonary artery (PA) anastomosis in the upper esophageal aortic arch (AoArch) short-axis view.

Tricuspid Regurgitation.—There is no consensus regarding the value of concurrent TV procedures at the time of LVAD implantation. Some studies suggest that concurrent tricuspid procedures reduce hospitalization, incidence of right heart failure (RHF), and postoperative renal dysfunction.^{72,73} However, a more recent analysis of the Interagency Registry for Mechanically Assisted Circulatory Support showed that concurrent TV surgery in patients with moderate and severe TR did not confer any survival benefit compared with patients who underwent LVAD implantation alone.⁷⁴ As mentioned in section 3.3.2, evaluation of TR is complex and should include not only color flow and spectral Doppler interrogation of the regurgitant jet, but also assessment of (1) tricuspid annulus dimensions, (2) tricuspid leaflet tethering, (3) size of the RA, RV and inferior vena cava, and (4) position and motion of the IAS and IVS.

Aortic Regurgitation.—AR in patients undergoing LVAD implantation is likely to progress due to lack of aortic valve opening, leaflet fibrosis, and fusion and retraction of the leaflet tips. The International Society of Heart Lung Transplantation recommends correction of moderate or higher degrees of pre-existing AR at the time of LVAD placement, since this may impact the long-term function and durability of the device.⁷⁰ In patients with advanced heart failure, elevated LV diastolic pressure and reduced systemic vascular resistance combine to reduce the diastolic pressure gradient across the AV, which leads to underestimation of AR severity before LVAD implantation. Re-evaluation of AR should be repeated after institution of CPB when the LV is decompressed and there is direct flow into the ascending aorta through the aortic cannula, which may mimic to some degree the hemodynamic conditions during LVAD support.

Table 19 Key points for imaging pre- and postprocedure in patients undergoing heart transplantation

Imaging goals	Imaging views	Imaging modalities
PREPROCEDURE		
Evaluate ascending aorta and main PA Rule out masses/thrombus at the future anastomotic site	ME: ascending aorta SAX/LAX UE: aortic arch SAX TG: basal RV, RV inflow/outflow Epicardial	<ul style="list-style-type: none"> • 2D, bi/multiplane imaging • 3D
Evaluate IVC and SVC Rule out masses/thrombus/stenosis at the future anastomotic site	ME: bicaval (slight probe withdrawal for SVC, slight probe advancement for IVC), ascending aorta SAX	<ul style="list-style-type: none"> • 2D, bi/multiplane imaging • CFD
Evaluate intracardiac thrombus LAA LV apex	ME: 4/5Ch, MC, 2Ch, LAX	<ul style="list-style-type: none"> • 2D, biplane/multiplane imaging • 3D • Spectral Doppler (LAA velocities)
Extracardiac structures Pleural effusions Ascites	ME: 4/5 Ch (turn probe left for left pleural space, turn probe right for right pleural space) TG views for evaluation of ascites	<ul style="list-style-type: none"> • 2D
POSTPROCEDURE		
Left ventricle Size Systolic function: regional (wall motion abnormalities) and global (FAC, SV, EF); Diastolic function (TMF, mitral annulus velocities)	ME: 4/5 Ch, 2Ch, LAX TG: basal SAX, mid SAX, 2Ch, deep 5Ch	<ul style="list-style-type: none"> • 2D, bi/multiplane imaging • 3D • Spectral Doppler • Tissue Doppler
Right ventricle Size (IVS and motion) Systolic function (free wall, FAC, TAPSE), RVOT SV	ME: 4Ch, RV inflow/outflow TG: basal RV, RV inflow, RV inflow/outflow	<ul style="list-style-type: none"> • 2D, bi/multiplane imaging • CFD • Spectral Doppler
Comprehensive evaluation of all valves	ME and TG views	<ul style="list-style-type: none"> • 2D • CFD • 3D • Spectral Doppler
Evaluate ascending aorta and main PA anastomosis Rule out stenosis/thrombus (absence of discrete narrowing, flow acceleration)	ME: ascending aorta SAX/LAX UE: aortic arch SAX TG: basal RV, RV inflow/outflow Epicardial	<ul style="list-style-type: none"> • 2D, bi/multiplane imaging • CFD • Spectral Doppler
Evaluate IVC and SVC anastomosis Rule out stenosis/thrombus (absence of discrete narrowing, flow acceleration)	ME: bicaval (slight probe withdrawal for SVC, slight probe advancement for IVC), ascending aorta SAX	<ul style="list-style-type: none"> • 2D, bi/multiplane imaging • CFD
Evaluate LA anastomosis Rule out stenosis (absence of flow acceleration)	ME: 4Ch, 2Ch, LAX	<ul style="list-style-type: none"> • 2D • CFD

Abbreviations: 2Ch, Two-chamber; 4Ch, four-chamber; 5Ch, five-chamber; 2D, two-dimensional; 3D, three-dimensional; CFD, color flow Doppler; EF, ejection fraction; FAC, fractional area change; IVC, inferior vena cava; IVS, interventricular septum; LA, left atrium; LAA, left atrial appendage; LAX, long axis; MC, mitral commissural; ME, mid-esophageal; PA, pulmonary artery; RA, right atrium; RV, right ventricle; RVOT, right ventricular outflow tract; SAX, short axis; SV, stroke volume; SVC, superior vena cava; TAPSE, tricuspid annular plane systolic excursion; TG, transgastric; UE, upper esophageal.

Mitral Regurgitation.—The severity of MR may be significantly reduced after LVAD implantation through reverse remodeling and improved leaflet coaptation. Emerging data indicate that patients with residual MR after LVAD implantation may have persistent pulmonary hypertension and worse RV function; however, the evidence is not compelling enough to recommend surgical intervention for moderate or severe MR in these patients,⁷⁵ unless there is expectation for myocardial recovery and subsequent LVAD removal.

Mitral Stenosis.—A significant diastolic gradient across the MV will lead to impaired LVAD filling, persistence of pulmonary venous pressure elevation, and symptoms of heart failure. Therefore, patients with MS and a mean pressure gradient >10 mm Hg should be considered for MV replacement at the time of LVAD implantation. Caution must be exercised in the presence of a number of factors which can influence transmitral flow, such as atrial fibrillation and tachycardia. The transmitral pressure gradient may underestimate the severity of

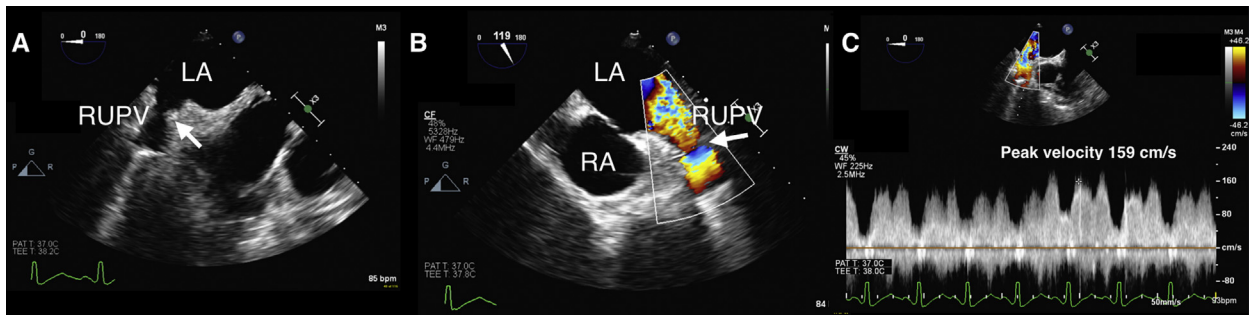


Figure 15 (A) ME right upper pulmonary vein (RUPV) view showing possible narrowing (*white arrow*). (B) Color flow Doppler interrogation of the RUPV shows flow acceleration (*white arrow*) at the level of narrowing. (C) Continuous-wave Doppler interrogation of the RUPV showing velocities of 159 cm/s. Evaluation of pulmonary vein velocities should be made within the clinical context. Abbreviations: LA, Left atrium; RA, right atrium.

Table 20 Key points for imaging in patients undergoing lung transplantation

Imaging goals	Imaging views	Imaging modalities
PREPROCEDURE		
Establish baseline ventricular (RV, LV) and valvular function (MV, TV, AV, PV)	ME and TG views	<ul style="list-style-type: none"> • 2D, bi/multiplane imaging • 3D • CFD • Spectral Doppler
Evaluate intracardiac shunts PFO ASD Agitated saline study with Valsalva maneuver	ME: 4/5Ch, bicaval	<ul style="list-style-type: none"> • 2D, bi/multiplane imaging • CFD
Evaluate pulmonary vein velocities (left and right) Establish baseline velocities and flow profile for comparison post-transplantation	ME: MC, 2Ch, bicaval	<ul style="list-style-type: none"> • 2D • CFD • Spectral Doppler
POSTPROCEDURE		
Evaluate pulmonary vein velocities (left and right) Rule-out stenosis/kinking/thrombus	ME: MC, 2Ch, bicaval Epicardial (if imaging not adequate by TEE)	<ul style="list-style-type: none"> • 2D • CFD • Spectral Doppler
Evaluate pulmonary artery anastomoses Rule out stenosis/kinking/thrombus; Limited visibility of the left PA because of interposition of the left main bronchus	ME: ascending aorta SAX/LAX UE: aortic arch SAX TG: basal RV, RV inflow/outflow Epicardial	<ul style="list-style-type: none"> • 2D • CFD • Spectral Doppler
Evaluate ventricular (RV, LV) and valvular function (MV, TV, AV, PV)	ME and TG views	<ul style="list-style-type: none"> • 2D, bi/multiplane imaging • 3D • CFD • Spectral Doppler

Abbreviations: 2Ch, Two-chamber; 4Ch, four-chamber; 5Ch, five-chamber; 2D, two-dimensional; 3D, three-dimensional; ASD, atrial septal defect; AV, aortic valve; CFD, color flow Doppler; LA, left atrium; LAA, left atrial appendage; LAX, long axis; LV, left ventricle; MC, mitral commissural; ME, mid-esophageal; MV, mitral valve; PA, pulmonary artery, PFO, patent foramen ovale; PV, pulmonic valve; RV, right ventricle; RVOT, right ventricle outflow tract; SAX, short axis; TEE, transesophageal echocardiography; TG, transgastric; TV, tricuspid valve; UE, upper esophageal.

MS in the presence of low cardiac output, elevated LV diastolic pressure, and low flow across the MV. Other methods, such as planimetry using multiplanar reconstruction of a three-dimensional data set, should be used in these situations.⁷⁶

Prosthetic Heart Valves.—The presence of prosthetic heart valves (PHV) is not considered a contraindication for MCS.⁷⁷ However, due to the low-flow state in the LVAD candidate, the range of motion of leaflets/disks of a PHV may be limited and may result in thrombus

Table 21 Key points for intraoperative imaging in patients with pericardial diseases

Imaging goals	Imaging views	Imaging modalities
PREPROCEDURE		
Evaluate presence and extent of effusion Size and location (may be loculated) Free wall compression/inversion: RA (systolic) RV (diastolic inversion) LA (systolic)	ME: 4/5 Ch, RV inflow/outflow, LAX, bicaval TG: basal SAX, mid SAX, TG RV inflow, RV inflow/outflow	<ul style="list-style-type: none"> • 2D, bi/multiplane imaging • M-mode: timing of free wall inversion
Evaluation of other structures: Oblique sinus: fluid/clot around the pulmonary veins Transverse sinus: fluid/clot around the great vessels Compression of LAA	ME: 2Ch, MC, AV LAX, ascending aorta SAX/LAX, bicaval	<ul style="list-style-type: none"> • 2D, bi/multiplane imaging • CFD
Evaluate exaggerated ventricular interdependence Respirophasic changes in transvalvular flow; Positive pressure ventilation: during inhalation decrease in transtricuspid flow and increase in transmitral flow; May be absent in patients with pericardiectomy or loculated effusions IVS bounce—constrictive pericarditis	ME: 4Ch, RV inflow/outflow, bicaval	<ul style="list-style-type: none"> • 2D • Spectral Doppler (PW Doppler across TV and MV)
In constrictive pericarditis: Evaluate annulus reversus (lateral $e' < \text{septal } e'$)	ME: 4 Ch	<ul style="list-style-type: none"> • Tissue Doppler imaging (PW Doppler at lateral and septal mitral annulus)
POSTPROCEDURE		
Evaluate resolution of pericardial clot or fluid	ME: 4/5 Ch, RV inflow/outflow, LAX, bicaval TG: basal SAX, mid SAX, TG RV inflow, RV inflow/outflow	<ul style="list-style-type: none"> • 2D, bi/multiplane imaging
Evaluate ventricular (RV, LV) and valvular function (MV, TV, AV, PV) after drainage/pericardiectomy	ME and TG views	<ul style="list-style-type: none"> • 2D • CFD • 3D • Spectral Doppler

Abbreviations: 2Ch, Two-chamber; 4Ch, four-chamber; 5Ch, five-chamber; 2D, two-dimensional; 3D, three-dimensional; AV, aortic valve; CFD, color flow Doppler; e' , early diastolic mitral annular velocity; IVS, interventricular septum; LA, left atrium; LAA, left atrial appendage; LAX, long axis; LV, left ventricle; MC, mitral commissural; ME, mid-esophageal; MV, mitral valve; PV, pulmonic valve; PW, pulsed-wave; RV, right ventricle; SAX, short axis; TG, transgastric; TV, tricuspid valve.

or pannus formation in the patient supported by an LVAD.⁷⁸ The assessments of gradients at the time of LVAD insertion will be critical for follow up evaluations by TTE.

Right Ventricular Function.—The development of RHF in LVAD recipients is associated with poor outcomes,⁷⁹ as optimal LVAD performance depends on an adequately functional RV to provide effective preload to the pump. While LVAD support may enhance RV performance by decreasing pulmonary hypertension and thus RV afterload, the presence of the LVAD may also worsen RV function by increasing its preload. Alteration in RV geometry after pericardiectomy and loss of pericardial constraint, as well as changes in the contribution of septal contraction, may impact overall RV function after LVAD implantation. A comprehensive assessment of RV function is presented in Table 1. RV fractional area change (FAC), together with tricuspid annular plane systolic excursion (TAPSE), represent the mainstay of RV function assessment in clinical practice. However, there is a

body of evidence that in patients undergoing cardiac surgery with cardiopulmonary bypass and complete pericardiectomy, the patterns of contraction of the RV change, with a decrease in longitudinal shortening relative to transverse shortening, rendering TAPSE less reliable in assessing RV function in these clinical situations.⁸⁰ So far, no echocardiographic variables have consistently emerged as predictors of RHF after LVAD implantation and purely qualitative assessment of RV performance, showing more than moderate RV dysfunction, still remains highly predictive of RHF.⁸¹

Intracardiac Shunts.—The presence of an intracardiac shunt can result in right-to-left flow with hypoxemia and possible paradoxical embolism after LVAD implantation. Although it is possible to find an ASD or a VSD, the most common cause of an intra-cardiac shunt is the presence of a PFO. TEE examination required for PFO identification includes 2D echocardiographic assessment and CFD interrogation, optimized for detection of low-velocity flow across the PFO.⁸²

Table 22 Key points for intraoperative imaging in patients undergoing resection of intracardiac masses

PREPROCEDURE
Evaluate location, size, type of attachment
Evaluate effect on neighboring structures and associated findings (e.g., pericardial effusion)
Evaluate malignant vs. benign features as outlined in the text
POSTPROCEDURE
Evaluate extent of resection
Exclude iatrogenic damage that may have occurred to neighboring structures during resection
Perform a complete examination following resection in order to uncover pathologies that may have been obscured by the presence of the tumor/mass

Agitated saline injection along with a Valsalva release maneuver is used to unmask right-to-left shunting. Special attention should be given to patients who have an atrial septal aneurysm or a Chiari network as these anatomical findings can be associated more commonly with the presence of a PFO.⁸³ Also, in the presence of severe LV dysfunction and very elevated LA pressure it may be difficult to raise the RA pressure above the LA pressure with the Valsalva maneuver, leading to a false-negative bubble study.⁶⁷

Left Ventricle and Left Atrium.—Blood stasis due to decreased blood flow or arrhythmias (e.g., atrial fibrillation) may result in the formation of thrombus in the LV or the LA. The planned sites of inflow (LV apex) and outflow (aorta) cannula placement should be imaged. Epi-aortic ultrasound may be indicated in the latter circumstance.

A proposed algorithm for preprocedure imaging in patients undergoing LVAD implantation is presented in [Figure 5](#).

6.1.2. Postprocedure Assessment. Intraoperative TEE should be performed prior to and shortly after activation of the newly implanted LVAD. In addition, TEE should be performed whenever changes in hemodynamics or device parameters occur, as well as at the time of sternal closure. Device speed should be recorded as a text annotation on the images and loops recorded for reference and comparison with subsequent imaging studies.

De-Airing.—Air bubbles must be detected prior to activation of the LVAD pump in order to decrease the possibility of air embolism. As LVADs can generate negative intraventricular pressure and a suction effect, attention should be paid not only to removal of intracardiac air but also to entrainment and reintroduction of air by the pump.

Inflow Cannula.—In an optimal position, the LVAD inflow cannula placed in the LV apex is aligned with the MV opening, away from the interventricular septum and the lateral wall. It should be routinely evaluated by 2D, 3D, CFD, and spectral Doppler echocardiography at the ME level ([Figure 6](#)). CFD interrogation at the inflow cannula opening should demonstrate low-velocity, unidirectional, non-turbulent flow. In addition, unobstructed flow should be demonstrated using CW or PW Doppler from the inflow cannula with peak velocities of 1-2 m/s.⁷¹ A characteristic artifact, previously described as the “waterfall artifact”, is generated by the intrapericardial presence of the HeartWare HVAD impeller, which degrades both color and spectral Doppler assessment of the inflow cannula in these devices at the ME level.⁸⁴

Outflow Cannula.—The outflow cannula of most LVADs is positioned in the ascending aorta. This cannula can be seen in the ME AV SAX or LAX views. Interrogation of velocities with CW Doppler should show velocities less than 2 m/s. Flow acceleration and higher velocities can be seen if there is obstruction at the anastomotic site. However, if the obstruction is remote from the anastomotic site, the velocities may be low, with a faint Doppler signal, and have less systolic-to-diastolic variability.⁷¹ Of note, current recommended reference values do not take in consideration differences in pump designs and outflow graft size for the newer devices. Recent reports have suggested that velocities as high as 3.4 m/s may be within normal range for the HeartWare HVAD device.⁸⁵

All the components of the pre-implantation TEE exam should be repeated. A PFO may be detectable only after LVAD implantation. This can occur in 20% of cases where a PFO was undetectable in the pre-implantation examination.⁸⁶ The presence of AR should be evaluated and quantified. With more than mild AR, consideration should be given to surgical correction. M-mode of the AV leaflets can demonstrate the degree and frequency of valve opening.

The presence of the LVAD as well as the effects of cardiopulmonary bypass may transiently worsen RV function and TR through changes in the geometry of the RV and TV apparatus. Also, in the immediate post-implantation period, TEE provides continuous physiologic information regarding LV unloading, patient volume status, and RV function. Ideally, the interventricular septum is positioned midline, without leftward bowing. Excessive leftward ventricular septal deviation or “suck-down”, i.e., a decrease in LV size accompanied by RV dilation and dysfunction, indicates decreased preload to the LVAD in the setting of RV failure and should prompt a reduction in LVAD speed and simultaneous efforts toward augmenting LV preload. Conversely, rightward deviation of the interventricular septum indicates insufficient LVAD unloading and an increase in pump speed is warranted. A decrease in size of both ventricles indicates hypovolemia.

A proposed algorithm for postprocedure imaging in patients undergoing LVAD implantation is presented in [Figure 7](#).

Key points for the pre- and postprocedure assessment in patients undergoing durable LVAD implantation are presented in [Table 11](#).

6.2. Percutaneous Devices

The Impella[®] Catheter (Abiomed, Inc., Danvers, MA) provides partial mechanical support via an intravascular microaxial pump. The device is most commonly inserted via the femoral artery or axillary artery

and advanced across the AV. When positioned properly, the catheter delivers blood from an inlet in the LV to its outlet in the ascending aorta.

A pre-implantation examination should follow the algorithm proposed in [Figure 5](#). However, specific findings that may preclude the placement of this system are: (1) a heavily calcified and stenosed AV, (2) a mechanical prosthetic AV, (3) narrowing of the LV outflow tract due to hypertrophic cardiomyopathy or any other form of sub-aortic stenosis, and (4) a redundant, myxomatous MV that may obstruct the inlet of the device.⁸⁷ While the presence of severe AR may not preclude placement of the system, it can result in ineffective LV emptying and decreased forward flow with poor systemic perfusion.

For positioning guidance, the best echocardiographic view is the ME LAX as it visualizes the device from the ascending aorta into the LV apex. For optimal positioning of this device, the inlet area should be about 4-4.5 cm below the AV, the outlet area should be well above the AV, and the catheter should angle toward the LV apex, away from the LV wall and the MV.⁸⁸ The position of the inlet and outlet areas can be approximated by the artifacts they generate: in the ME AV LAX view, the inlet zone (seen in the far field in the LV) will lead to generation of a hypoechoic area due to acoustic shadowing, while the outlet housing (seen in the near field in the ascending aorta) will generate a significant reverberation artifact. Also, if a device is positioned correctly, interrogation by CFD should show a mosaic pattern of turbulence around the outlet area, well above the AV.⁸⁸

Complications associated with the use of an Impella device include AV injury, MV injury or traction on the subvalvular apparatus with new or worsened MR, cardiac perforation, aortic dissection, and vascular injury.^{89,90}

Key points for imaging in patients undergoing placement of an Impella device are presented in [Table 12](#).

6.3. Right Ventricular Assist Devices

Extracorporeal centrifugal pumps for support of the failing right heart can be implanted: (1) via sternotomy (CentriMag, Thoratec, Pleasanton, CA); (2) percutaneously via the femoral vein (Impella RP, Abiomed, Danvers, MA); or (3) percutaneously via the right internal jugular vein (Protek Duo, Cardiac Assist, Inc., Pittsburgh, PA).

The presence of mechanical TV or PV prostheses precludes placement of a percutaneous, catheter-based assist device. TV function should be assessed using 2D, CFD, and spectral Doppler echocardiography. While TR is typically well-tolerated during RVAD support, the presence of more than mild PR may limit the efficacy of device outflow delivered to the PA. The presence of masses in the right heart chambers or PA could lead to device obstruction or pulmonary embolism.

The inflow of a catheter-based RVAD should be located at the RA-IVC junction (Impella RP) or RA-SVC junction (Protek Duo). The RVAD outflow in the main PA should be positioned far enough from the PV so as not to interfere with valve opening, worsen regurgitation, or direct a portion of the outflow into the RV ([Figure 8](#)). Similarly, if the RVAD is positioned in or directed predominantly into the right or left pulmonary artery, one lung will be preferentially overperfused. The degree of RV decompression during device support should be interpreted in light of the pump speed, which should ideally be annotated on the echocardiographic image. The degree of RV decompression varies; extracorporeal centrifugal pumps can generate flow in excess of 9 L/minute, while catheter-based devices generally operate at about 4 L/minute. A lack of expected RV decom-

pression may also herald worsening of PR, potentially due to outflow cannula malposition.

Key points for the pre- and postprocedure assessment for RVAD implantation are presented in [Table 13](#).

6.4. Total Artificial Heart

Implantation of a total artificial heart (TAH, SynCardia, Inc., Tucson, AZ) may be considered in patients with irreversible biventricular heart failure, either as a bridge to transplantation or as destination therapy. The TAH comprises two rigid neo-ventricles containing polyurethane diaphragms. An atrial connector joins the neo-ventricles to the preserved tricuspid and mitral annuli while the outflows of the device are connected to the pulmonary artery and aorta by means of short tube grafts that replace the proximal portions of these vessels.⁹¹ The cyclic passage of air via drivelines from an external control console results in the excursion of polyurethane diaphragms within the neo-ventricles, creating a repetitive filling and ejection of blood. Prior to implantation of the TAH, all four cardiac valves are excised together with the majority of both ventricles. The TAH includes 27 mm Medtronic-Hall (Medtronic, Inc, Minneapolis, MN) tilting disk valves in the tricuspid and mitral positions and 25 mm Medtronic-Hall valves in the pulmonary and aortic positions. Given the nature of the procedure, the intraoperative TEE assessment of native valve pathology or ventricular function prior to TAH implantation is of little importance.⁹¹ However, since the native atria are retained, it is important to thoroughly examine these structures along with their venous inflow prior to TAH placement. Right and left pulmonary venous diameters, flow profiles, and velocities should be documented at baseline and compared to those post TAH. The LAA should be inspected for thrombus and intravascular medical devices should not extend past the RA-SVC junction.^{91,92} A proposed algorithm for preprocedure imaging in patients undergoing TAH implantation is presented in [Figure 9](#).

Following TAH implantation, imaging of the native atria, their inflow veins, and mechanical prosthetic heart valves is done in the ME views. At the time of weaning from cardiopulmonary bypass, TEE imaging is used to monitor intracardiac air evacuation. Residual air (in the main PA and ascending aorta) should be differentiated from micro-cavitation, which is sometimes visualized as tiny bubbles appearing along the margins of rapidly closing mechanical heart valves. Intense acoustic reverberations and other imaging artifacts result from the presence of 4 mechanical valves, rigid neo-ventricles, and pneumatically-driven diaphragms. Mean prosthetic valve gradients are often similar to values encountered in patients with native ventricles,⁹¹ although they may be influenced by device settings.⁹³ If TAH flows are adequate, peak PV velocities up to 2 m/sec may be acceptable.⁹¹ Mean gradients and the corresponding ventricular rate should be recorded for the tricuspid and mitral prostheses in order to serve as a reference for subsequent examinations.

The placement of rigid neo-ventricles within the mediastinum creates the potential for kinking or compression of venous inflow into the atria.^{91,92} Obstruction of the RA-IVC junction is more common than RA-SVC obstruction, and intrahepatic IVC dilatation may be observed along with reduced hepatic vein flow velocities.^{91,94} Obstruction of pulmonary venous inflow is suspected if there is loss of phasic systolic and diastolic flow patterns, particularly if color Doppler flow acceleration is detected and peak velocities are increased above normal or baseline values.⁹¹ Filling of the neo-ventricles may be augmented by the application of suction.

Typically, suction is not added until the mediastinum is closed. Excessive suction levels at a given volume status may generate a suction event, or suck-down. This may manifest as the appearance of an LA mass or may simulate an inverted LAA as the LA wall is pulled inward. Resolution of the mass coincident with a reduction in device suction confirms the diagnosis.⁹⁵

A proposed algorithm for postprocedure imaging in patients undergoing TAH implantation is presented in [Figure 10](#). Key points for imaging during TAH implantation are presented in [Table 14](#).

6.5. Extracorporeal Membrane Oxygenation

Echocardiography plays multiple roles in the management of extracorporeal membrane oxygenation (ECMO). TEE is used to determine the type of ECMO needed (veno-venous [VV] vs. veno-arterial [VA]), ensure proper positioning of cannulas, assess the extent of ventricular decompression, monitor and diagnose complications, and evaluate potential myocardial recovery for subsequent decision-making.⁹⁶ In order to provide pertinent information, the echocardiographer should have a complete understanding of the intended cannulation strategy (e.g., peripheral vs. central) and the type of cannula(s) to be used (single-stage vs. dual-stage venous cannula, or bicaval venous cannulations).

Pre-deployment echocardiographic examination should characterize biventricular systolic function in order to determine the type of ECMO circuit required (VV or VA).

Factors that may limit inflow to the ECMO circuit, such as vascular stenosis or intracardiac masses, should be excluded. Congenital heart disease and related surgical interventions must be thoroughly characterized in order to facilitate an acceptable cannulation strategy. Similarly, factors that might compromise or complicate VA ECMO outflow, such as severe AR, aortic dissection, or significant atherosclerotic burden, should be recognized. The presence of interatrial or interventricular shunts (PFO, ASD, VSD) should be noted. A proposed imaging algorithm pre-ECMO deployment is presented in [Figure 11](#).

At the time of ECMO placement, TEE should establish cannula position, ensuring that inflow and outflow are not positioned in such proximity that recirculation occurs during VV ECMO (oxygenated circuit outflow is preferentially taken up by the inflow cannula, rather than entering the patient's circulation). Cannula position is reassessed during ECMO support, particularly if concerns arise regarding the efficacy of oxygenation or circulatory support. The degree of ventricular decompression should also be evaluated during ECMO support and should be interpreted in light of the circuit flow rate. At high VA ECMO flow rates, LV decompression should be observed. The lack of LV decompression may signal the presence of significant AR or collateral flow (bronchial circulation) and the need for LV vent placement. The presence of spontaneous echo contrast or thrombus in the area of low blood flow and stasis (LV apex, LAA, aortic root in the absence of AV opening) should be evaluated.

Finally, echocardiography plays a central role in determining readiness for weaning from ECMO. Numerous echo-derived measurements have been proposed as predictors of successful weaning from VA ECMO, including those derived by strain and tissue Doppler imaging.⁹⁷ Echocardiographic parameters that suggest a higher likelihood of weaning from ECMO include an LV ejection fraction >20-25%, an LVOT velocity-time integral >10 cm, a systolic mitral annular velocity by tissue Doppler imaging >6 cm/sec, and absence of LV or RV dilatation.⁹⁸

A proposed imaging algorithm post-ECMO deployment is presented in [Figure 12](#). Key points for imaging in extracorporeal mem-

brane oxygenation deployment, monitoring, and weaning are presented in [Table 15](#).

6.6. Intra-aortic Balloon Pump

The IABP remains the most widely used MCS device in critically ill patients with cardiac disease. The majority of these devices are placed intraoperatively.

The pre-insertion TEE examination should document any contraindications to the use of an IABP such as the presence of greater than mild AR and aortic pathology such as aortic dissection or mobile atheromatous disease.

For maximal balloon augmentation, the optimal position of the IABP catheter tip is in the descending aorta, 1 to 2 cm distal to the left subclavian artery (LSCA). Malposition of the balloon catheter may compromise regional blood flow to the left arm or brain if it is positioned too high/proximal, or to the abdominal organs if too low/distal.^{99,100}

Assessment of IABP placement begins with visualization of the guidewire within the lumen of the descending aorta. The tip of the balloon is first identified in the descending aorta SAX view. Proper placement below the left subclavian artery (LSCA) is assessed by visualizing the tip of the IABP in the descending aorta LAX view and then slowly withdrawing the probe until the LSCA is seen at the level of the aortic arch (which is now seen in cross section). The distance from the tip of the balloon to the LSCA can be estimated by noting the difference between the depth of the probe when imaging the tip of the balloon and the depth of the probe when imaging the LSCA. Proper IABP function can be assessed by the presence of acoustic shadowing and reverberation artifacts during diastole when the balloon is inflated. Finally, TEE should assess the impact of counterpulsation on ventricular function. Key points regarding imaging for placement of the IABP are presented in [Table 16](#).

7. HYPERTROPHIC CARDIOMYOPATHY

Septal myectomy is considered the gold standard in the treatment of patients with hypertrophic cardiomyopathy (HCM) and dynamic obstruction of the LVOT. The goal of surgical intervention is to redirect the LV outflow anteriorly and medially, away from the MV leaflets. Surgical procedures performed in patients with HCM include: (1) classic subaortic septal resection,¹⁰¹ (2) extended myectomy,¹⁰² (3) papillary muscle release,¹⁰³ and (3) anterior mitral leaflet plication.¹⁰⁴ The extended myectomy involves resection of the myocardium past the coaptation point of the MV, allowing LV flow during systole to track anteriorly away from the mitral valve. The papillary muscle release allows the MV apparatus to drop posteriorly into the LV by dividing the connections between the papillary muscles and LV wall, thereby further separating the LV inflow and outflow. Plication of the anterior leaflet of the mitral valve shortens the redundant anterior leaflet, removing a predisposition to SAM.

The application of intraoperative TEE in guiding the surgical treatment of patients with HCM has been detailed in the ASE clinical recommendations for multimodality cardiovascular imaging for patients with HCM.¹⁰⁵ Some of the salient aspects of echocardiographic guidance are presented below.

7.1. Preprocedure Assessment

The patients presenting for septal myectomy have been comprehensively imaged preoperatively by TTE and cardiac magnetic resonance

imaging. However, by detailed anatomical and functional information, intraoperative TEE can further define the surgical plan.

Preoperatively, important goals of intraoperative TEE examination are to (1) describe the interventricular septum, (2) analyze the MV and subvalvular apparatus anatomy and describe the characteristics of the MR, and (3) further elucidate the factors contributing to LVOT obstruction.

Interventricular Septum.—The interventricular septum is best evaluated in the ME 4Ch, ME LAX, and TG midpapillary SAX views. It is paramount to describe the extent and location of septal thickening. Useful measurements are maximal thickness of the septum, apical extent of the septal bulge, and distance from the aortic annulus to mitral-septal contact. Multiplanar reconstruction of a 3D data set is best used in order to ensure that measurements are performed at the correct levels^{105,106} (Figure 13).

Mitral Regurgitation and Mitral Valve Apparatus.—MV and MR assessment are described in section 3.1.2. In HCM patients, MR related to SAM is posteriorly oriented and dynamic. SAM results in disruption of normal MV coaptation, as the posterior leaflet may not be long enough or mobile enough to follow the anterior leaflet in the LVOT, leading to an interleaflet gap. However, 10-20% of patients with HCM may have MR unrelated to SAM, due to a structural defect of the MV. In this case, the MR jet is oriented centrally or anteriorly.¹⁰⁷ Useful measurements include length of the anterior MV leaflet and residual length of the anterior leaflet of the MV beyond the coaptation point. An anterior leaflet length >16 mm/m² is considered elongated and may contribute to obstruction.¹⁰⁶ Measurements can be done in the ME LAX view or by multiplanar reconstruction of a 3D data set.

LVOT Obstruction.—CFD can be used to confirm the areas of flow convergence. Concomitant pathology generating obstruction (e.g., aortic stenosis, sub-aortic membrane) should be excluded. Spectral Doppler should be used to measure the peak velocity; a late-systolic “dagger”-shaped velocity envelope (concave ascending and late peaking morphology) with peak pressure gradient >30 mm Hg across the LVOT suggests flow obstruction. Contamination of the Doppler signal by MR should be excluded.

Key points for preprocedure assessment in patients undergoing septal myectomy are presented in Table 17.

7.2. Postprocedure Assessment

Postprocedure, intraoperative TEE should assess the adequacy of the surgical procedure and detect possible complications.

Adequacy of Surgical Procedure.—Postoperative gradients across the LVOT should be measured under optimized hemodynamic conditions. A repeat assessment should be performed under pharmacological challenge (e.g., dobutamine at 10 µg/kg/min and/or isoproterenol for an adequate increase in heart rate). Residual obstruction with LVOT velocities >3 m/s may necessitate return to CPB for additional repair.¹⁰² The same measurements of the IVS performed preprocedure should be repeated in order to assess the adequacy of the resection. The mitral valve should be re-evaluated to ensure resolution of SAM with improved coaptation and reduction in the severity of MR.

Complications.—An iatrogenic VSD should be excluded following myectomy by carefully examining the IVS with 2D images and with CFD to detect tissue discontinuity and abnormal flow traversing

the myocardium. VSDs are often best detected in the ME LAX or ME AV LAX views, but multiple views of the septum (including TG views) with CFD should be used. Flow through an iatrogenic VSD should be from left to right across the IVS, predominantly systolic. Small iatrogenic VSDs, however, may be difficult to visualize and may only be heralded by the presence of abnormal turbulent flow by CFD in the RV during systole.

It is important to distinguish a VSD from a severed septal branch of the left coronary artery (a coronary-cameral fistula). Laceration of septal perforators can be visualized by CFD in the ME 4Ch or LAX views and in the TG basal SAX, mid-papillary SAX, or deep 5Ch views. Such fistulas will demonstrate diastolic flow from the left side of the IVS into the LV at the site of the myectomy.¹⁰⁸ The flow of severed septal perforators should also be distinguished from eccentric aortic regurgitation. New onset aortic regurgitation may occur due to direct injury to the cusps.¹⁰⁵

Key points for imaging following septal myectomy are presented in Table 18.

8. HEART TRANSPLANTATION

There are multiple roles for intraoperative TEE in patients undergoing orthotopic heart transplantation (OHT): (1) intraoperative monitoring in the pre-transplantation period, (2) evaluation of the cardiac allograft function and surgical anastomoses in the immediate post-transplantation period, and (3) diagnosis and management of hemodynamic abnormalities.

Preprocedure Assessment.—Preprocedure TEE in the recipient undergoing orthotopic heart transplantation can (1) confirm the diagnosis and most importantly survey for its associated complications, and (2) assist with hemodynamic management in the pre-CPB period. Intracardiac blood stasis due to decreased blood flow in the setting of end-stage heart failure or arrhythmias may result in the formation of thrombus in the LV or the LA. Surgical manipulation in the pre-CPB period may dislodge thrombus and potentially result in an embolic stroke. The exam should also evaluate the future anastomotic sites for presence of atherosclerotic disease or thrombus: (1) ascending aorta- ME AV LAX, ME ascending aorta SAX/LAX, (2) main PA- ME ascending aorta SAX, UE aortic arch SAX, and (3) venae cavae- ME bicaval view, ME ascending aorta SAX. The examination may be challenging because of the presence of an existing MCS or other intracardiac apparatus such as an implantable rhythm management device.

Postprocedure Assessment.—A comprehensive TEE examination should be performed post transplantation and should include assessment of LV systolic and diastolic function, RV function, and valvular function.

Primary graft dysfunction due to LV, RV, or biventricular dysfunction occurs in up to 30% of patients.^{109,110} While isolated LV dysfunction is rare,^{109,110} RV dysfunction, either isolated or as part of biventricular dysfunction, is more common, seen in up to 50% of patients undergoing OHT.^{109,110} RV function evaluation, either by visual assessment or using quantitative parameters (Table 1), should be performed throughout the post-transplantation period, especially when unexplained hemodynamic instability is apparent.

Significant TR is the most common valvular abnormality after OHT, with a reported incidence as high as 84%, depending on the time of diagnosis and the criteria used.¹¹¹⁻¹¹⁴ In the immediate post-

transplantation period, significant TR may be due to geometric annular distortion (more common with the biatrial surgical technique¹¹⁵) and annular dilation in the presence of RV dysfunction.¹¹¹ Of importance is the fact that the severity of TR in the immediate post-CPB period is highly dynamic, being dependent on RV preload, afterload, and contractility. Several studies have shown that TR that develops after OHT does not lead to symptoms significant enough to warrant surgical treatment. More recently, Bishawi et al. showed that of the 21% of patients who had moderate or severe TR after separation from CPB, 91% showed regression of TR to mild or none. Only 1% of the patients who had moderate or severe TR underwent delayed TV repair.¹¹⁶ Other common valvular abnormalities encountered in OHT recipients are pulmonic regurgitation (42%), moderate MR (32%), and mild AR (23%).¹¹¹

In addition, the anastomotic sites of the great vessels, ascending aorta, main PA, IVC, and SVC should show no discrete areas of narrowing by 2D echocardiography and should demonstrate laminar flow by CFD (Figure 14). The same approaches used in the pre-procedure assessment may be used for evaluation of the great vessels after separation from CPB. Of note, in the immediate post-transplantation period, PA anastomotic stenosis due to mismatch in the size of anastomosed vessels, or suture constriction, torsion, or kinking is a reversible cause of RV dysfunction and should always be evaluated.¹¹⁷ IVC and SVC anastomotic stenosis can result in systemic venous hypertension and liver and renal failure,¹¹⁸ or SVC syndrome, respectively.¹¹⁹

The LA anastomotic suture line may appear as a prominent ridge on the posterior wall of the LA and the LA may appear enlarged. The presence of stenotic LA suture lines causing hemodynamically significant obstruction to flow (acquired cor triatriatum), which results in pulmonary venous hypertension and RV failure, has been described and should be excluded by inspecting the LA in the ME views.¹²⁰

Post-transplantation TEE examination also assists with advancement of the PA catheter, hemodynamic management in the post-CPB period, and deployment of MCS.

Key points for imaging pre- and postprocedure in patients undergoing heart transplantation are presented in Table 19.

9. LUNG TRANSPLANTATION

TEE is an invaluable diagnostic and imaging tool in patients undergoing lung transplantation. It has very well-defined applications during all stages of the procedure as well as in the immediate postoperative period in the intensive care unit. At all times during lung transplantation, TEE can differentiate among different causes of hemodynamic instability such as right ventricular failure, hypovolemia, myocardial ischemia with wall motion abnormalities, or pulmonary tamponade in cases of severe emphysema and lung hyperinflation.

Preprocedure Assessment.—Considering that candidates for lung transplantation experience variable delays awaiting transplantation, TEE should confirm findings of the preoperative workup regarding ventricular function and valvular lesions, especially with respect to RV function (Table 1) and TR (section 3.3.2). Specifically, significant RV dysfunction and dilation should be discussed with the surgical team as ECMO deployment may be required preemptively in anticipation of pulmonary artery clamping, or emergently during episodes of hypoxia, hypercarbia, or hemodynamic instability. Patients with chronic respiratory failure often have signs of RV pressure overload

with RV hypertrophy and free wall thickness >5 mm. Flattening of the interventricular septum results in a D-shaped LV throughout the cardiac cycle as seen in the ME 4Ch and TG mid-papillary SAX views.

TEE should also evaluate the presence of intracardiac shunts (e.g., PFO, ASD) that may warrant surgical closure at the time of transplantation with institution of CPB, or may require further work-up and transcatheter closure after lung transplantation. Pre-transplantation pulmonary vein flow velocities should be measured and compared with post-transplant assessment.¹²¹

During transplant, the hemodynamic effects of PA cross-clamping may induce acute RV failure, with echocardiographic findings of RA and RV dilatation with leftward displacement of the IAS and IVS, paradoxical IVS motion, and RV dysfunction. Removal of the LA clamp and reperfusion of the implanted lung can cause air embolization into the left heart.

Postprocedure Assessment.—Although vascular anastomotic complications are rare (reported at 1.8% in a cohort of 720 lung transplants¹²²), they contribute to graft dysfunction, and carry a high morbidity and mortality.¹²³ Early detection and resolution are important in preventing postoperative morbidity. A comprehensive examination of all vascular anastomoses by 2D, CFD, and spectral Doppler echocardiography is performed using multiple standard and modified TEE views.¹²⁴ All pulmonary vein anastomoses are carefully evaluated to exclude significant stenosis, which may be due to kinking, surgical sutures, or external compression. The presence of turbulent flow by CFD, a pulmonary vein diameter <0.5 cm, and a peak systolic velocity >1 m/s are indicative of significant anastomotic stenosis.¹²⁵ Caution must be exercised when making management decisions regarding surgical re-intervention. High-velocity flow could also indicate narrowing of the contralateral PA anastomosis, high pulmonary blood flow, or donor lung venoconstriction (Figure 15). Higher PV velocities occur in the transplanted single lung due to its lower pulmonary vascular resistance compared with the native lung. The presence of low PV flow velocity may be an early indication of a vascular complication. The differential of low PV flow velocities includes (1) flow obstruction from a narrowed anastomosis or (2) low pulmonary blood volume from hypovolemia or myocardial dysfunction. However, loss of phasic (systolic/diastolic) flow even in the presence of low velocities should raise the suspicion of stenosis and prompt further evaluation.¹²¹ The appearance of continuous air emboli observed by TEE at the end of lung transplantation should prompt re-examination of the integrity of the pulmonary venous anastomosis.

The pulmonary veins and LA should be carefully examined for the presence of thrombus, and if identified, the size, precise location and associated flow abnormalities noted. The overall rate of pulmonary vein thrombosis is low (15%) and generally involves the upper veins.^{126,127}

Pulmonary arterial anastomoses are considered normal if the minimal diameter of the anastomosis is at least 75% of the diameter of the proximal pulmonary artery and if color flow Doppler shows unobstructed flow through the anastomosis. While the right pulmonary artery can be imaged easily in the ME ascending aorta SAX view, the left pulmonary artery is difficult to image because of the interposition of the left bronchus. However, the left pulmonary artery can be imaged at the level of the proximal descending aorta, where it passes anteriorly to the left bronchus.

Left and right ventricular function should be reassessed. Patients undergoing lung transplantation may be prone to right ventricular outflow tract obstruction from a hyperdynamic and/or hypertrophied RV,¹²⁸ or compression from an oversized transplanted lung.¹²⁹

Epicardial echocardiography is an option when the vascular anastomosis cannot be visualized with TEE^{130,131} or in patients who have contraindications to TEE such as those with esophageal disorders (e.g., scleroderma).

Key points for imaging in patients undergoing lung transplantation are presented in [Table 20](#).

10. PERICARDIAL DISEASES

The role of echocardiography in diagnosing pericardial diseases has been detailed in published ASE recommendations.¹³² The section below will specifically highlight the role of intraoperative TEE in guiding surgery in patients with pericardial diseases.

Pericardial Tamponade.—A circumferential pericardial effusion, the classic echocardiographic finding of pericardial tamponade, is usually absent in patients who have recently undergone cardiac surgery or catheter-based cardiac procedures.¹³³ Pericardial tamponade after cardiac surgery has various, non-specific clinical presentations and the typical echocardiographic finding is a localized pericardial collection. The combination of surgical dressings, chest tubes, supine positioning, and mechanical ventilation makes TEE the preferred imaging technique¹³⁴ to visualize cardiac chamber compression due to localized thrombus, and TEE is less likely to yield a false-negative report when compared with TTE. Along with confirming the diagnosis, intraoperative TEE should be used to exclude other unrecognized causes of heart failure. TEE should also document the presence of a circumferential or localized pericardial fluid accumulation, masses/thrombus, fibrin strands (floating linear structures of variable size and length) and their effect on cardiac chamber structure and function. Positive pressure mechanical ventilation augments the pattern of respiratory-related transvalvular flow change¹³²; i.e., a decrease in early mitral inflow velocities (ME 4Ch or ME LAX view) is expected together with an increase in early tricuspid inflow velocities (ME 4Ch or ME modified bicaval view) during mechanical exhalation.^{135,136}

Following surgical exploration and pericardial evacuation, intraoperative TEE should be repeated with the goal of documenting removal of accumulated pericardial fluid and clot, particularly along the posterior aspect of the heart (e.g., fluid or clot visualized in the oblique sinus), which is more difficult to visualize in the surgical field. The same views should be used to compare cardiac chamber size and blood velocities, before and after pericardial evacuation. However, a repeat comprehensive TEE examination following relief of tamponade can also serve to document biventricular function and detect other abnormalities, such as valvular disease that may have been difficult to appreciate before pericardial evacuation due to extrinsic compression and reduced cardiac filling.

Constrictive Pericarditis.—The patients presenting to the operating room for pericardiectomy for constrictive pericarditis have typically been comprehensively imaged and diagnosed by several imaging modalities in the preoperative work-up.¹³² In this clinical context, the diagnostic role of intraoperative TEE may be limited. Nonetheless, the echocardiographer should be familiar with the salient echocardiographic features of constrictive pericarditis. In constrictive pericarditis with exaggerated ventricular interdependence, rapidly changing pressure gradients between the RV and the LV, particularly in early diastole, result in the characteristic septal bounce.¹³⁷ Characteristic tissue Doppler findings include *annulus reversus*, in which lateral wall tethering causes the lateral mitral annular e' velocity to decrease

below medial mitral annular e' velocity, and *annulus paradoxus*, in which preservation/enhancement of the medial mitral annular e' velocity creates an inverse correlation between mitral E/e' and LV filling pressures.¹³⁸ In the presence of positive pressure ventilation, similar respirophasic changes in transmitral and transtricuspid velocities may be seen as in pericardial tamponade.¹³²

Following pericardiectomy, a comprehensive TEE examination should be repeated and an assessment of biventricular function as well as an interrogation of valvular function should be performed once the pericardial restraint to cardiac filling has been alleviated. Transient RV dysfunction immediately after pericardiectomy has been described, possibly due to myocardial atrophy with prolonged pericardial constriction, and abrupt increase in venous return, which can lead to heart failure with volume overload after pericardial decompression.¹³⁹

Key points for intraoperative imaging in patients with pericardial diseases are presented in [Table 21](#).

11. TUMORS AND INTRACARDIAC MASSES

Echocardiography is the primary diagnostic modality for the assessment of cardiac tumors. Echocardiographers performing an intraoperative TEE examination should be familiar with the echocardiographic appearance of intracardiac tumors, as well as with the limitations of TEE in imaging tumors and masses.

The TEE examination should be focused on the structural features of a mass, its anatomic location and extension, type of attachment (smooth vs. pedunculated), relative size and effect on neighboring cardiac structures (valve regurgitation or obstruction, chamber obliteration), and associated findings (pericardial effusion, tamponade). Local invasion and hypervascularity (often seen as flow within the mass at lower Nyquist limit) are typical for malignant tumors, while benign tumors have poor blood supply and thrombi are avascular. Other features suggestive of malignancy include a location outside of the left atrium, involvement of more than one cardiac chamber, broad-based attachment, extension to the mediastinum or great vessels, presence of multiple masses, and pericardial effusion.¹⁴⁰

Masses and tumors should be differentiated from normal anatomic variants, embryologic remnants (e.g., “coumadin ridge”, moderator band, false tendons, Chiari network, Lambd’s excrescences, crista terminalis, or nodules of Arantius), or common artifacts.

Complete understanding of normal anatomy and variants along with embryologic remnants, as well as postoperative or postprocedural structural changes, is critical to avoid misdiagnosis. TEE is best suited for visualization of posterior structures.¹⁴¹ 2D echocardiography with simultaneous multiplane imaging may allow better characterization of a mass and enable differentiation from normal cardiac structures or artifacts. TEE is not ideal for imaging anterior structures that lie in the far field (thrombus in LV apex, masses on PV leaflets), and in the patient with sternotomy, epicardial echocardiogram is an alternative approach.

Key points for pre- and postprocedure assessment in patients undergoing intracardiac tumor resection are presented in [Table 22](#).

12. SUMMARY

Intraoperative TEE is a versatile diagnostic and monitoring tool to assist in patient management in a wide range of cardiac surgical procedures, even more so in the current era of increased complexity and

decreased invasiveness of procedures being performed. Even when patients present to the operating room after having been investigated comprehensively, it is important to perform a complete pre-procedure echocardiographic examination in a systematic manner whenever possible. Utilizing a “catch-all” protocol as a starting point for imaging in all procedures and all patients enables standardization of image acquisition, reduction in variability in quality of imaging and reporting, and ultimately better patient care. Clear communication of the echocardiographic findings to the surgical team, as well as understanding the impact of new findings on the surgical plan, are paramount. Equally important is the need for an informed understanding of the technical steps of the surgical procedures being performed and the complications that may occur, in order to direct the postprocedure evaluation toward aspects directly related to the surgical procedure and to provide pertinent echocardiographic information.

Ultimately, it is important that the intraoperative echocardiographer be an integral and active part of the heart team. A team-based, collaborative approach will not only enhance delivery of personalized, patient-centric care, but also elevate the team members through the cognitive exchange that occurs across specialties.

NOTICE AND DISCLAIMER: This report is made available by ASE as a courtesy reference source for members. This report contains recommendations only and should not be used as the sole basis to make medical practice decisions or for disciplinary action against any employee. The statements and recommendations contained in this report are primarily based on the opinions of experts, rather than on scientifically-verified data. ASE makes no express or implied warranties regarding the completeness or accuracy of the information in this report, including the warranty of merchantability or fitness for a particular purpose. In no event shall ASE be liable to you, your patients, or any other third parties for any decision made or action taken by you or such other parties in reliance on this information. Nor does your use of this information constitute the offering of medical advice by ASE or create any physician-patient relationship between ASE and your patients or anyone else.

Reviewers: This document was reviewed by members of the ASE Guidelines and Standards Committee, ASE Board of Directors, ASE Executive Committee, and designated representatives from the Society of Cardiovascular Anesthesiologists and Society of Thoracic Surgeons. Reviewers included Scott D. Choyce, RDCS, RVT, RDMS, FASE, Edward Gill, MD, FASE, David Harrild, MD, FASE, Dawn S. Hui, MD, Renuka Jain, MD, FASE, William Katz, MD, FASE, Stephen H. Little, MD, FASE, Anuj Mediratta, MD, FASE, David Orsinelli, MD, FASE, Alan S. Pearlman, MD, FASE, Andrew Pellett, PhD, RDCS, FASE, David H. Wiener, MD, FASE, Megan Yamat, RDCS, RCS, FASE.

REFERENCES

1. Practice guidelines for perioperative transesophageal echocardiography. An updated report by the American Society of Anesthesiologists and the Society of Cardiovascular Anesthesiologists Task Force on Transesophageal Echocardiography. *Anesthesiology* 2010;112:1084-96.
2. Zoghbi WA, Adams D, Bonow RO, Enriquez-Sarano M, Foster E, Grayburn PA, et al. Recommendations for noninvasive evaluation of native valvular regurgitation: a report from the American Society of Echocardiography developed in collaboration with the Society for Cardiovascular Magnetic Resonance. *J Am Soc Echocardiogr* 2017;30:303-71.
3. Baumgartner H, Hung J, Bermejo J, Chambers JB, Edvardsen T, Goldstein S, et al. Recommendations on the echocardiographic assessment of aortic valve stenosis: a focused update from the European Association of Cardiovascular Imaging and the American Society of Echocardiography. *J Am Soc Echocardiogr* 2017;30:372-92.
4. Puchalski MD, Lui GK, Miller-Hance WC, Brook MM, Young LT, Bhat A, et al. Guidelines for performing a comprehensive transesophageal echocardiographic examination in children and all patients with congenital heart disease: recommendations from the American Society of Echocardiography. *J Am Soc Echocardiogr* 2019;32:173-215.
5. Mor-Avi V, Lang RM, Badano LP, Belohlavek M, Cardim NM, Derumeaux G, et al. Current and evolving echocardiographic techniques for the quantitative evaluation of cardiac mechanics: ASE/EAE consensus statement on methodology and indications endorsed by the Japanese Society of Echocardiography. *J Am Soc Echocardiogr* 2011;24:277-313.
6. Lang RM, Badano LP, Tsang W, Adams DH, Agricola E, Buck T, et al. EAE/ASE recommendations for image acquisition and display using three-dimensional echocardiography. *J Am Soc Echocardiogr* 2012;25:3-46.
7. Practice guidelines for perioperative transesophageal echocardiography. A report by the American Society of Anesthesiologists and the Society of Cardiovascular Anesthesiologists Task Force on Transesophageal Echocardiography. *Anesthesiology* 1996;84:986-1006.
8. Hahn RT, Abraham T, Adams MS, Bruce CJ, Glas KE, Lang RM, et al. Guidelines for performing a comprehensive transesophageal echocardiographic examination: recommendations from the American Society of Echocardiography and the Society of Cardiovascular Anesthesiologists. *J Am Soc Echocardiogr* 2013;26:921-64.
9. Lang RM, Badano LP, Mor-Avi V, Afilalo J, Armstrong A, Ernande L, et al. Recommendations for cardiac chamber quantification by echocardiography in adults: an update from the American Society of Echocardiography and the European Association of Cardiovascular Imaging. *J Am Soc Echocardiogr* 2015;28:1-39.e14.
10. Block M, Hourigan L, Bellows WH, Reeves J 3rd, Romson JL, Tran M, et al. Comparison of left atrial dimensions by transesophageal and transthoracic echocardiography. *J Am Soc Echocardiogr* 2002;15:143-9.
11. Parikh SS, Jons C, McNitt S, Daubert JP, Schwarz KQ, Hall B. Predictive capability of left atrial size measured by CT, TEE, and TTE for recurrence of atrial fibrillation following radiofrequency catheter ablation. *Pacing Clin Electrophysiol* 2010;33:532-40.
12. Baumgartner H, Hung J, Bermejo J, Chambers JB, Evangelista A, Griffin BP, et al. Echocardiographic assessment of valve stenosis: EAE/ASE recommendations for clinical practice. *J Am Soc Echocardiogr* 2009;22:1-23; quiz 101-2.
13. Drake DH, Zimmerman KG, Hepner AM, Nichols CD. Echo-guided mitral repair. *Circ Cardiovasc Imaging* 2014;7:132-41.
14. Maslow AD, Regan MM, Haering JM, Johnson RG, Levine RA. Echocardiographic predictors of left ventricular outflow tract obstruction and systolic anterior motion of the mitral valve after mitral valve reconstruction for myxomatous valve disease. *J Am Coll Cardiol* 1999;34:2096-104.
15. Alfieri O, Lapenna E. Systolic anterior motion after mitral valve repair: where do we stand in 2015? *Eur J Cardiothorac Surg* 2015;48:344-6.
16. Cobey FC, Ashikhmina E, Edrich T, Fox J, Shook D, Bollen B, et al. The mechanism of mitral regurgitation influences the temporal dynamics of the vena contracta area as measured with color flow Doppler. *Anesth Analg* 2016;122:321-9.
17. Mihalatos DG, Gopal AS, Kates R, Toole RS, Bercow NR, Lamendola C, et al. Intraoperative assessment of mitral regurgitation: role of phenylephrine challenge. *J Am Soc Echocardiogr* 2006;19:1158-64.
18. Del Rio JM, Grecu L, Nicoara A. Right ventricular function in left heart disease. *Semin Cardiothorac Vasc Anesth* 2019;23:88-107.
19. Siegel LC, St Goar FG, Stevens JH, Pompili MF, Burdon TA, Reitz BA, et al. Monitoring considerations for port-access cardiac surgery. *Circulation* 1997;96:562-8.
20. Applebaum RM, Colvin SB, Galloway AC, Ribakove GH, Grossi EA, Tunick PA, et al. The role of transesophageal echocardiography during

- port-access minimally invasive cardiac surgery: a new challenge for the echocardiographer. *Echocardiography* 1999;16:595-602.
21. Labriola C, Greco F, Braccio M, Dambrosio PP, Labriola G, Paparella D. Percutaneous coronary sinus catheterization with the proplege catheter under transesophageal echocardiography and pressure guidance. *J Cardiothorac Vasc Anesth* 2015;29:598-604.
 22. Maslow A. Mitral valve repair: an echocardiographic review: part 2. *J Cardiothorac Vasc Anesth* 2015;29:439-71.
 23. Trzcinka A, Fox JA, Shook DC, Hilberath JN, Hartman G, Bollen B, et al. Echocardiographic evaluation of mitral inflow hemodynamics after asymmetric double-orifice repair. *Anesth Analg* 2014;119:1259-66.
 24. Maslow A, Mahmood F, Poppas A, Singh A. Three-dimensional echocardiographic assessment of the repaired mitral valve. *J Cardiothorac Vasc Anesth* 2014;28:11-7.
 25. Ibrahim M, Rao C, Ashrafian H, Chaudhry U, Darzi A, Athanasiou T. Modern management of systolic anterior motion of the mitral valve. *Eur J Cardiothorac Surg* 2012;41:1260-70.
 26. Zoghbi WA, Chambers JB, Dumesnil JG, Foster E, Gottdiener JS, Grayburn PA, et al. Recommendations for evaluation of prosthetic valves with echocardiography and Doppler ultrasound: a report from the American Society of Echocardiography's Guidelines and Standards Committee and the Task Force on Prosthetic Valves, developed in conjunction with the American College of Cardiology Cardiovascular Imaging Committee, Cardiac Imaging Committee of the American Heart Association, the European Association of Echocardiography, a registered branch of the European Society of Cardiology, the Japanese Society of Echocardiography and the Canadian Society of Echocardiography. *J Am Soc Echocardiogr* 2009;22:975-1014; quiz 82-4.
 27. Konoske R, Whitener G, Nicoara A. Intraoperative evaluation of paravalvular regurgitation by transesophageal echocardiography. *Anesth Analg* 2015;121:329-36.
 28. O'Rourke DJ, Palac RT, Malenka DJ, Marrin CA, Ar buckle BE, Plehn JF. Outcome of mild periprosthetic regurgitation detected by intraoperative transesophageal echocardiography. *J Am Coll Cardiol* 2001;38:163-6.
 29. LaBounty TM, Miyasaka R, Chetcuti S, Grossman PM, Deeb GM, Patel HJ, et al. Annulus instead of LVOT diameter improves agreement between echocardiography effective orifice area and invasive aortic valve area. *JACC Cardiovasc Imaging* 2014;7:1065-6.
 30. Michelena HI, Pibarot P, Enriquez-Sarano M. Echocardiographic severity grading in aortic stenosis: no holy grail, only lessons towards patient individualisation. *Heart* 2014;100:4-5.
 31. Hahn RT, Nicoara A, Kapadia S, Svensson L, Martin R. Echocardiographic imaging for transcatheter aortic valve replacement. *J Am Soc Echocardiogr* 2018;31:405-33.
 32. Hahn RT, Khalique O, Williams MR, Koss E, Paradis JM, Daneault B, et al. Predicting paravalvular regurgitation following transcatheter valve replacement: utility of a novel method for three-dimensional echocardiographic measurements of the aortic annulus. *J Am Soc Echocardiogr* 2013;26:1043-52.
 33. Otani K, Takeuchi M, Kaku K, Sugeng L, Yoshitani H, Haruki N, et al. Assessment of the aortic root using real-time 3D transesophageal echocardiography. *Circ* 2010;74:2649-57.
 34. Nishimura RA, Otto CM, Bonow RO, Carabello BA, Erwin JP 3rd, Guyton RA, et al. 2014 AHA/ACC guideline for the management of patients with valvular heart disease: executive summary: a report of the American College of Cardiology/American Heart Association Task Force on Practice Guidelines. *J Am Coll Cardiol* 2014;63:2438-88.
 35. Uda Y, Cowie B, Kluger R. Comparison of preoperative and intraoperative assessment of aortic stenosis severity by echocardiography. *Br J Anaesth* 2017;118:699-704.
 36. Boodhwani M, El Khoury G. Aortic valve repair: indications and outcomes. *Curr Cardiol Rep* 2014;16:490.
 37. Mangini A, Contino M, Romagnoni C, Lemma M, Gelpi G, Vanelli P, et al. Aortic valve repair: a ten-year single-centre experiencedagger. *Interact Cardiovasc Thorac Surg* 2014;19:28-35.
 38. Svensson LG, Al Kindi AH, Vivacqua A, Pettersson GB, Gillinov AM, Mihaljevic T, et al. Long-term durability of bicuspid aortic valve repair. *Ann Thorac Surg* 2014;97:1539-47. discussion 48.
 39. Boodhwani M, de Kerchove L, Glineur D, Poncelet A, Rubay J, Astarci P, et al. Repair-oriented classification of aortic insufficiency: impact on surgical techniques and clinical outcomes. *J Thorac Cardiovasc Surg* 2009;137:286-94.
 40. El Khoury G, Glineur D, Rubay J, Verhelst R, d'Acoz Y, Poncelet A, et al. Functional classification of aortic root/valve abnormalities and their correlation with etiologies and surgical procedures. *Curr Opin Cardiol* 2005;20:115-21.
 41. Berrebi A, Monin JL, Lansac E. Systematic echocardiographic assessment of aortic regurgitation-what should the surgeon know for aortic valve repair? *Ann Cardiothorac Surg* 2019;8:331-41.
 42. Van Dyck MJ, Watremez C, Boodhwani M, Vanoverschelde JL, El Khoury G. Transesophageal echocardiographic evaluation during aortic valve repair surgery. *Anesth Analg* 2010;111:59-70.
 43. Augoustides JG, Szeto WY, Bavaria JE. Advances in aortic valve repair: focus on functional approach, clinical outcomes, and central role of echocardiography. *J Cardiothorac Vasc Anesth* 2010;24:1016-20.
 44. Barbanti M, Webb JG, Hahn RT, Feldman T, Boone RH, Smith CR, et al. Impact of preoperative moderate/severe mitral regurgitation on 2-year outcome after transcatheter and surgical aortic valve replacement: insight from the Placement of Aortic Transcatheter Valve (PARTNER) Trial Cohort A. *Circulation* 2013;128:2776-84.
 45. Harling L, Saso S, Jarral OA, Kourliouros A, Kidher E, Athanasiou T. Aortic valve replacement for aortic stenosis in patients with concomitant mitral regurgitation: should the mitral valve be dealt with? *Eur J Cardiothorac Surg* 2011;40:1087-96.
 46. Caballero-Borrego J, Gomez-Doblas JJ, Cabrera-Bueno F, Garcia-Pinilla JM, Melero JM, Porras C, et al. Incidence, associated factors and evolution of non-severe functional mitral regurgitation in patients with severe aortic stenosis undergoing aortic valve replacement. *Eur J Cardiothorac Surg* 2008;34:62-6.
 47. Matsumura Y, Gillinov AM, Toyono M, Oe H, Yamano T, Takasaki K, et al. Echocardiographic predictors for persistent functional mitral regurgitation after aortic valve replacement in patients with aortic valve stenosis. *Am J Cardiol* 2010;106:701-6.
 48. Ruel M, Kapila V, Price J, Kulik A, Burwash IG, Mesana TG. Natural history and predictors of outcome in patients with concomitant functional mitral regurgitation at the time of aortic valve replacement. *Circulation* 2006;114(1 Suppl):I541-6.
 49. Bartunek J, Sys SU, Rodrigues AC, van Schuerbeeck E, Mortier L, de Bruyne B. Abnormal systolic intraventricular flow velocities after valve replacement for aortic stenosis. Mechanisms, predictive factors, and prognostic significance. *Circulation* 1996;93:712-9.
 50. Bierbach BO, Aicher D, Issa OA, Bomberg H, Graber S, Glombitza P, et al. Aortic root and cusp configuration determine aortic valve function. *Eur J Cardiothorac Surg* 2010;38:400-6.
 51. le Polain de Waroux JB, Pouleur AC, Robert A, Pasquet A, Gerber BL, Noirhomme P, et al. Mechanisms of recurrent aortic regurgitation after aortic valve repair: predictive value of intraoperative transesophageal echocardiography. *JACC Cardiovasc Imaging* 2009;2:931-9.
 52. Ancona F, Agricola E, Stella S, Capogrosso C, Marini C, Margonato A, et al. Interventional imaging of the tricuspid valve. *Interv Cardiol Clin* 2018;7:13-29.
 53. Chikwe J, Itagaki S, Anyanwu A, Adams DH. Impact of concomitant tricuspid annuloplasty on tricuspid regurgitation, right ventricular function, and pulmonary artery hypertension after repair of mitral valve prolapse. *J Am Coll Cardiol* 2015;65:1931-8.
 54. Fukuda S, Song JM, Gillinov AM, McCarthy PM, Daimon M, Kongsareepong V, et al. Tricuspid valve tethering predicts residual tricuspid regurgitation after tricuspid annuloplasty. *Circulation* 2005;111:975-9.
 55. Seguela PE, Roubertie F, Thambo JB. Distortion of the left anterior descending coronary artery after pulmonary valve replacement. *Catheter Cardiovasc Interv* 2016;88:99-102.

56. Suradi HS, Hijazi ZM. Percutaneous pulmonary valve implantation. *Glob Cardiol Sci Pract* 2015;2015:23.
57. Swaminathan M, Nicoara A, Phillips-Bute BG, Aeschlimann N, Milano CA, Mackensen GB, et al. Utility of a simple algorithm to grade diastolic dysfunction and predict outcome after coronary artery bypass graft surgery. *Ann Thorac Surg* 2011;91:1844-50.
58. Gelzinis TA. New insights into diastolic dysfunction and heart failure with preserved ejection fraction. *Semin Cardiothorac Vasc Anesth* 2014;18:208-17.
59. Biancari F, Santini F, Tauriainen T, Bancone C, Ruggieri VG, Perrotti A, et al. Epi-aortic ultrasound to prevent stroke in coronary artery bypass grafting. *Ann Thorac Surg* 2020;109:294-301.
60. Goldstein SA, Evangelista A, Abbara S, Arai A, Asch FM, Badano LP, et al. Multimodality imaging of diseases of the thoracic aorta in adults: from the American Society of Echocardiography and the European Association of Cardiovascular Imaging: endorsed by the Society of Cardiovascular Computed Tomography and Society for Cardiovascular Magnetic Resonance. *J Am Soc Echocardiogr* 2015;28:119-82.
61. LePage MA, Quint LE, Sonnad SS, Deeb GM, Williams DM. Aortic dissection: CT features that distinguish true lumen from false lumen. *AJR Am J Roentgenol* 2001;177:207-11.
62. Baliga RR, Nienaber CA, Bossone E, Oh JK, Isselbacher EM, Sechtem U, et al. The role of imaging in aortic dissection and related syndromes. *JACC Cardiovasc Imaging* 2014;7:406-24.
63. Movsowitz HD, Levine RA, Hilgenberg AD, Isselbacher EM. Transesophageal echocardiographic description of the mechanisms of aortic regurgitation in acute type A aortic dissection: implications for aortic valve repair. *J Am Coll Cardiol* 2000;36:884-90.
64. Mazzucotelli JP, Deleuze PH, Baufreton C, Duval AM, Hillion ML, Loisanse DY, et al. Preservation of the aortic valve in acute aortic dissection: long-term echocardiographic assessment and clinical outcome. *Ann Thorac Surg* 1993;55:1513-7.
65. White GH, Yu W, May J. Endoleak—a proposed new terminology to describe incomplete aneurysm exclusion by an endoluminal graft. *J Endovasc Surg* 1996;3:124-5.
66. Hughes GC, Sulzer CF, McCann RL, Swaminathan M. Endovascular approaches to complex thoracic aortic disease. *Semin Cardiothorac Vasc Anesth* 2008;12:298-319.
67. Williams JB, Andersen ND, Bhattacharya SD, Scheer E, Piccini JP, McCann RL, et al. Retrograde ascending aortic dissection as an early complication of thoracic endovascular aortic repair. *J Vasc Surg* 2012;55:1255-62.
68. Kirklin JK, Pagani FD, Kormos RL, Stevenson LW, Blume ED, Myers SL, et al. Eighth annual INTERMACS report: special focus on framing the impact of adverse events. *J Heart Lung Transplant* 2017;36:1080-6.
69. Rogers JG, Pagani FD, Tatroles AJ, Bhat G, Slaughter MS, Birks EJ, et al. Intrapericardial left ventricular assist device for advanced heart failure. *N Engl J Med* 2017;376:451-60.
70. Feldman D, Pamboukian SV, Teuteberg JJ, Birks E, Lietz K, Moore SA, et al. The 2013 International Society for Heart and Lung Transplantation guidelines for mechanical circulatory support: executive summary. *J Heart Lung Transplant* 2013;32:157-87.
71. Stainback RF, Estep JD, Agler DA, Birks EJ, Bremer M, Hung J, et al. Echocardiography in the management of patients with left ventricular assist devices: recommendations from the American Society of Echocardiography. *J Am Soc Echocardiogr* 2015;28:853-909.
72. Piacentino V 3rd, Ganapathi AM, Stafford-Smith M, Hsieh MK, Patel CB, Simeone AA, et al. Utility of concomitant tricuspid valve procedures for patients undergoing implantation of a continuous-flow left ventricular device. *J Thorac Cardiovasc Surg* 2012;144:1217-21.
73. Piacentino V 3rd, Troupes CD, Ganapathi AM, Blue LJ, Mackensen GB, Swaminathan M, et al. Clinical impact of concomitant tricuspid valve procedures during left ventricular assist device implantation. *Ann Thorac Surg* 2011;92:1414-8; discussion 8-9.
74. Song HK, Gelow JM, Mudd J, Chien C, Tibayan FA, Hollifield K, et al. Limited utility of tricuspid valve repair at the time of left ventricular assist device implantation. *Ann Thorac Surg* 2016;101:2168-74.
75. Kassis H, Cherukuri K, Agarwal R, Kanwar M, Elapavaluru S, Sokos GG, et al. Significance of residual mitral regurgitation after continuous flow left ventricular assist device implantation. *JACC Heart Fail* 2017;5:81-8.
76. Fierro MA, Welsby IJ. Identification of severe mitral stenosis using real-time three-dimensional transesophageal echocardiography during a left ventricular assist device insertion. *Anesth Analg* 2016;123:1089-93.
77. Mokashi SA, Schmitto JD, Lee LS, Rawn JD, Bolman RM 3rd, Shekar PS, et al. Ventricular assist device in patients with prosthetic heart valves. *Artif Organs* 2010;34:1030-4.
78. Butany J, Leong SW, Rao V, Borger MA, David TE, Cunningham KS, et al. Early changes in bioprosthetic heart valves following ventricular assist device implantation. *Int J Cardiol* 2007;117:e20-3.
79. Soliman OII, Akin S, Muslem R, Boersma E, Manintveld OC, Krabatsch T, et al. Derivation and validation of a novel right-sided heart failure model after implantation of continuous flow left ventricular assist devices: the EUROMACS (European Registry for Patients with Mechanical Circulatory Support) Right-Sided Heart Failure Risk Score. *Circulation* 2018;137:891-906.
80. Raina A, Vaidya A, Gertz ZM, Susan C, Forfia PR. Marked changes in right ventricular contractile pattern after cardiothoracic surgery: implications for post-surgical assessment of right ventricular function. *J Heart Lung Transplant* 2013;32:777-83.
81. Bellavia D, Iacovoni A, Scardulla C, Moja L, Pilato M, Kushwaha SS, et al. Prediction of right ventricular failure after ventricular assist device implant: systematic review and meta-analysis of observational studies. *Eur J Heart Fail* 2017;19:926-46.
82. Silvestry FE, Cohen MS, Armsby LB, Burkule NJ, Fleishman CE, Hijazi ZM, et al. Guidelines for the echocardiographic assessment of atrial septal defect and patent foramen ovale: from the American Society of Echocardiography and Society for Cardiac Angiography and Interventions. *J Am Soc Echocardiogr* 2015;28:910-58.
83. Kerut EK, Norfleet WT, Plotnick GD, Giles TD. Patent foramen ovale: a review of associated conditions and the impact of physiological size. *J Am Coll Cardiol* 2001;38:613-23.
84. Lesicka A, Feinman JW, Thiele K, Andrawes MN. Echocardiographic artifact induced by heartware left ventricular assist device. *Anesth Analg* 2015;120:1208-11.
85. Grinstein J, Kruse E, Collins K, Sayer G, Fedson S, Kim GH, et al. Screening for outflow cannula malfunction of left ventricular assist devices (LVADs) with the use of Doppler echocardiography: new LVAD-specific reference values for contemporary devices. *J Card Fail* 2016;22:808-14.
86. Liao KK, Miller L, Toher C, Ormaza S, Herrington CS, Bittner HB, et al. Timing of transesophageal echocardiography in diagnosing patent foramen ovale in patients supported with left ventricular assist device. *Ann Thorac Surg* 2003;75:1624-6.
87. Catena E, Milazzo F, Pittella G, Paino R, Colombo T, Garatti A, et al. Echocardiographic approach in a new left ventricular assist device: Impella Recover 100. *J Am Soc Echocardiogr* 2004;17:470-3.
88. Patel KM, Sherwani SS, Baudo AM, Salvacion A, Herborn J, Soong W, et al. Echo rounds: the use of transesophageal echocardiography for confirmation of appropriate Impella 5.0 device placement. *Anesth Analg* 2012;114:82-5.
89. Toggweiler S, Jamshidi P, Erne P. Functional mitral stenosis: a rare complication of the Impella assist device. *Eur J Echocardiogr* 2008;9:412-3.
90. Chandola R, Cusimano R, Osten M, Horlick E. Severe aortic insufficiency secondary to 5L Impella device placement. *J Card Surg* 2012;27:400-2.
91. Mizuguchi KA, Padera RF Jr, Kowalczyk A, Doran MN, Couper GS, Fox AA. Transesophageal echocardiography imaging of the total artificial heart. *Anesth Analg* 2013;117:780-4.
92. Zimmerman H, Coehlo-Anderson R, Slepian M, Smith RG, Sethi G, Copeland JG. Device malfunction of the CardioWest total artificial heart secondary to catheter entrapment of the tricuspid valve. *ASAIO J* 2010;56:481-2.

93. Fine NM, Gopalan RS, Arabia FA, Kushwaha SS, Chandrasekaran K. Intraoperative transesophageal echocardiographic guidance of total artificial heart implantation. *J Heart Lung Transplant* 2014;33:454-7.
94. Rehfeldt KH, Wittwer ED, Mauermann WJ. Inferior vena cava obstruction after total artificial heart implantation. *Anesth Analg* 2014;119:26-9.
95. Maldonado Y, Troianos CA, Marks B, Zhang Q, Dishart M. Echo rounds: intraoperative transesophageal echocardiography of a left atrial mass after total artificial heart implantation. *Anesth Analg* 2013;117:587-9.
96. Platts DG, Sedgwick JF, Burstow DJ, Mullany DV, Fraser JF. The role of echocardiography in the management of patients supported by extracorporeal membrane oxygenation. *J Am Soc Echocardiogr* 2012;25:131-41.
97. Doufle G, Roscoe A, Billia F, Fan E. Echocardiography for adult patients supported with extracorporeal membrane oxygenation. *Crit Care* 2015;19:326.
98. Aissaoui N, El-Banayasy A, Combes A. How to wean a patient from veno-arterial extracorporeal membrane oxygenation. *Intensive Care Med* 2015;41:902-5.
99. Shanewise JS, Sadel SM. Intraoperative transesophageal echocardiography to assist the insertion and positioning of the intraaortic balloon pump. *Anesth Analg* 1994;79:577-80.
100. Klopman MA, Chen EP, Sniecinski RM. Positioning an intraaortic balloon pump using intraoperative transesophageal echocardiogram guidance. *Anesth Analg* 2011;113:40-3.
101. Morrow AG, Brockenbrough EC. Surgical treatment of idiopathic hypertrophic subaortic stenosis: technic and hemodynamic results of subaortic ventriculomyotomy. *Ann Surg* 1961;154:181-9.
102. Sherrid MV, Chaudhry FA, Swistel DG. Obstructive hypertrophic cardiomyopathy: echocardiography, pathophysiology, and the continuing evolution of surgery for obstruction. *Ann Thorac Surg* 2003;75:620-32.
103. Messmer BJ. Extended myectomy for hypertrophic obstructive cardiomyopathy. *Ann Thorac Surg* 1994;58:575-7.
104. Balaram SK, Ross RE, Sherrid MV, Schwartz GS, Hillel Z, Winson G, et al. Role of mitral valve plication in the surgical management of hypertrophic cardiomyopathy. *Ann Thorac Surg* 2012;94:1990-7; discussion 7-8.
105. Nagueh SF, Bierig SM, Budoff MJ, Desai M, Dilsizian V, Eidem B, et al. American Society of Echocardiography clinical recommendations for multimodality cardiovascular imaging of patients with hypertrophic cardiomyopathy: endorsed by the American Society of Nuclear Cardiology, Society for Cardiovascular Magnetic Resonance, and Society of Cardiovascular Computed Tomography. *J Am Soc Echocardiogr* 2011;24:473-98.
106. Nampiaparampil RG, Swistel DG, Schlame M, Saric M, Sherrid MV. Intraoperative two- and three-dimensional transesophageal echocardiography in combined myectomy-mitral operations for hypertrophic cardiomyopathy. *J Am Soc Echocardiogr* 2018;31:275-88.
107. Yu EH, Omran AS, Wigle ED, Williams WG, Siu SC, Rakowski H. Mitral regurgitation in hypertrophic obstructive cardiomyopathy: relationship to obstruction and relief with myectomy. *J Am Coll Cardiol* 2000;36:2219-25.
108. Sgalambro A, Olivotto I, Rossi A, Nistri S, Baldini K, Baldi M, et al. Prevalence and clinical significance of acquired left coronary artery fistulas after surgical myectomy in patients with hypertrophic cardiomyopathy. *J Thorac Cardiovasc Surg* 2010;140:1046-52.
109. Nicoara A, Ruffin D, Cooter M, Patel CB, Thompson A, Schroder JN, et al. Primary graft dysfunction after heart transplantation: incidence, trends, and associated risk factors. *Am J Transplant* 2018;18:1461-70.
110. Segovia J, Cosio MD, Barcelo JM, Bueno MG, Pavia PG, Burgos R, et al. RADIAL: a novel primary graft failure risk score in heart transplantation. *J Heart Lung Transplant* 2011;30:644-51.
111. Cladellas M, Oriol A, Caralps JM. Quantitative assessment of valvular function after cardiac transplantation by pulsed Doppler echocardiography. *Am J Cardiol* 1994;73:1197-201.
112. Kwon MH, Shemin RJ. Tricuspid valve regurgitation after heart transplantation. *Ann Cardiothorac Surg* 2017;6:270-4.
113. Wong RC, Abrahams Z, Hanna M, Pangrace J, Gonzalez-Stawinski G, Starling R, et al. Tricuspid regurgitation after cardiac transplantation: an old problem revisited. *J Heart Lung Transplant* 2008;27:247-52.
114. Chan MC, Giannetti N, Kato T, Kornbluth M, Oyer P, Valentine HA, et al. Severe tricuspid regurgitation after heart transplantation. *J Heart Lung Transplant* 2001;20:709-17.
115. Koch A, Remppis A, Dengler TJ, Schnabel PA, Hagl S, Sack FU. Influence of different implantation techniques on AV valve competence after orthotopic heart transplantation. *Eur J Cardiothorac Surg* 2005;28:717-23.
116. Bishawi M, Zanotti G, Shaw L, MacKenzie M, Castleberry A, Bartels K, et al. Tricuspid valve regurgitation immediately after heart transplant and long-term outcomes. *Ann Thorac Surg* 2019;107:1348-55.
117. Gonzalez Saldivar H, Hortal J, Martin de Miguel I, Rodriguez-Abella H, Las CJ, Martinez-Selles M. A reversible cause of acute right ventricular failure after heart transplant. *Rev Esp Cardiol (Engl Ed)* 2017;70:677-9.
118. Jacobsohn E, Avidan MS, Hantler CB, Rosemeier F, De Wet CJ. Case report: inferior vena-cava right atrial anastomotic stenosis after bicaval orthotopic heart transplantation. *Can J Anaesth* 2006;53:1039-43.
119. Kashani BS, Ahmadi ZH, Abdi S, Mirhosseini SM, Kianfar AA, Niusha S. Superior vena cava obstruction after heart transplantation. *Asian Cardiovasc Thorac Ann* 2016;24:88-90.
120. Oaks TE, Rayburn BK, Brown ME, Kon ND. Acquired cor triatriatum after orthotopic cardiac transplantation. *Ann Thorac Surg* 1995;59:751-3.
121. Cartwright BL, Jackson A, Cooper J. Intraoperative pulmonary vein examination by transesophageal echocardiography: an anatomic update and review of utility. *J Cardiothorac Vasc Anesth* 2013;27:111-20.
122. Siddique A, Bose AK, Ozalp F, Butt TA, Muse H, Morley KE, et al. Vascular anastomotic complications in lung transplantation: a single institution's experience. *Interact Cardiovasc Thorac Surg* 2013;17:625-31.
123. Schulman LL, Anandarangam T, Leibowitz DW, Ditullio MR, McGregor CC, Galantowicz ME, et al. Four-year prospective study of pulmonary venous thrombosis after lung transplantation. *J Am Soc Echocardiogr* 2001;14:806-12.
124. Serra E, Feltracco P, Barbieri S, Forti A, Ori C. Transesophageal echocardiography during lung transplantation. *Transplant Proc* 2007;39:1981-2.
125. Gonzalez-Fernandez C, Gonzalez-Castro A, Rodriguez-Borregan JC, Lopez-Sanchez M, Suberviola B, Francisco Nistal J, et al. Pulmonary venous obstruction after lung transplantation. Diagnostic advantages of transesophageal echocardiography. *Clin Transplant* 2009;23:975-80.
126. Michel-Cherqui M, Brusset A, Liu N, Raffin L, Schlumberger S, Ceddaha A, et al. Intraoperative transesophageal echocardiographic assessment of vascular anastomoses in lung transplantation. A report on 18 cases. *Chest* 1997;111:1229-35.
127. McIlroy DR, Sesto AC, Buckland MR. Pulmonary vein thrombosis, lung transplantation, and intraoperative transesophageal echocardiography. *J Cardiothorac Vasc Anesth* 2006;20:712-5.
128. Gorcsan J 3rd, Reddy SC, Armitage JM, Griffith BP. Acquired right ventricular outflow tract obstruction after lung transplantation: diagnosis by transesophageal echocardiography. *J Am Soc Echocardiogr* 1993;6(3 Pt 1):324-6.
129. Denault AY, Couture P, McKenty S, Boudreault D, Plante F, Perron R, et al. Perioperative use of transesophageal echocardiography by anesthesiologists: impact in noncardiac surgery and in the intensive care unit. *Can J Anaesth* 2002;49:287-93.
130. Catena E, Paino R, Fieschi S, Rinaldo A, Milazzo F, Dejuli E, et al. Lung transplantation and pulmonary vein thrombosis: a possible role of epicardial echocardiography. *J Cardiothorac Vasc Anesth* 2008;22:167-8.
131. Felten ML, Michel-Cherqui M, Sage E, Fischler M. Transesophageal and contact ultrasound echographic assessments of pulmonary vessels in bilateral lung transplantation. *Ann Thorac Surg* 2012;93:1094-100.
132. Klein AL, Abbata S, Agler DA, Appleton CP, Asher CR, Hoit B, et al. American Society of Echocardiography clinical recommendations for multimodality cardiovascular imaging of patients with pericardial disease: endorsed by the Society for Cardiovascular Magnetic Resonance and Society of Cardiovascular Computed Tomography. *J Am Soc Echocardiogr* 2013;26:965-1012.e15.
133. Saito Y, Donohue A, Attai S, Vahdat A, Brar R, Handapangoda I, et al. The syndrome of cardiac tamponade with "small" pericardial effusion. *Echocardiography* 2008;25:321-7.

134. Imren Y, Tasoglu I, Oktar GL, Benson A, Naseem T, Cheema FH, et al. The importance of transesophageal echocardiography in diagnosis of pericardial tamponade after cardiac surgery. *J Card Surg* 2008;23:450-3.
135. Abdalla IA, Murray RD, Awad HE, Stewart WJ, Thomas JD, Klein AL. Reversal of the pattern of respiratory variation of Doppler inflow velocities in constrictive pericarditis during mechanical ventilation. *J Am Soc Echocardiogr* 2000;13:827-31.
136. Faehrich JA, Noone RB Jr., White WD, Leone BJ, Hilton AK, Sreeram GM, et al. Effects of positive-pressure ventilation, pericardial effusion, and cardiac tamponade on respiratory variation in transmitral flow velocities. *J Cardiothorac Vasc Anesth* 2003;17:45-50.
137. Coylewright M, Welch TD, Nishimura RA. Mechanism of septal bounce in constrictive pericarditis: a simultaneous cardiac catheterisation and echocardiographic study. *Heart* 2013;99:1376.
138. Ha JW, Ommen SR, Tajik AJ, Barnes ME, Ammass NM, Gertz MA, et al. Differentiation of constrictive pericarditis from restrictive cardiomyopathy using mitral annular velocity by tissue Doppler echocardiography. *Am J Cardiol* 2004;94:316-9.
139. Yu HT, Ha JW, Lee S, Shim CY, Moon J, Cho JJ, et al. Transient right ventricular dysfunction after pericardiectomy in patients with constrictive pericarditis. *Korean Circ J* 2011;41:283-6.
140. Kupsky DF, Newman DB, Kumar G, Maleszewski JJ, Edwards WD, Klarich KW. Echocardiographic features of cardiac angiosarcomas: the Mayo Clinic experience (1976-2013). *Echocardiography* 2016;33:186-92.
141. Lobo A, Lewis JF, Conti CR. Intracardiac masses detected by echocardiography: case presentations and review of the literature. *Clin Cardiol* 2000;23:702-8.